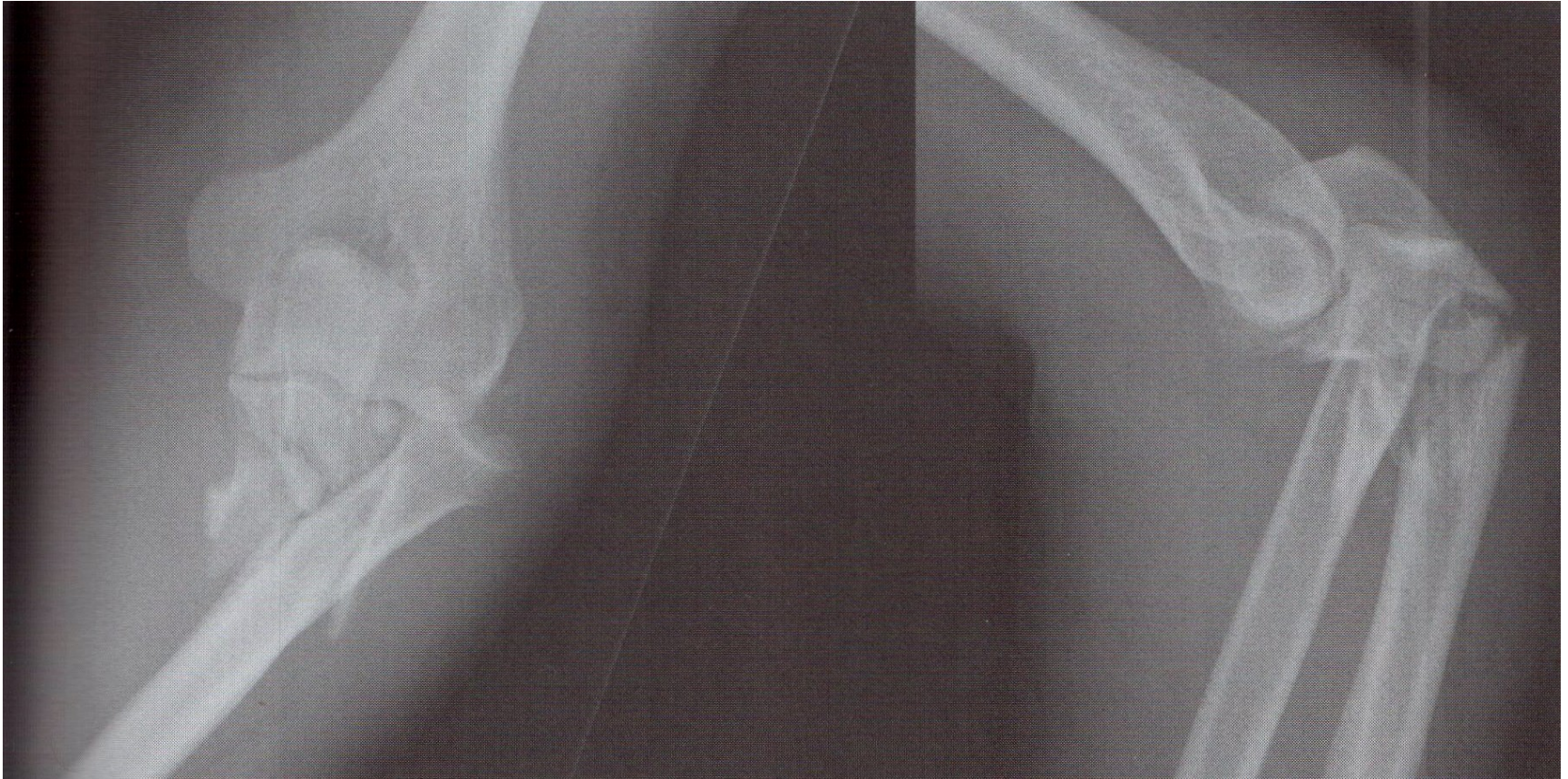
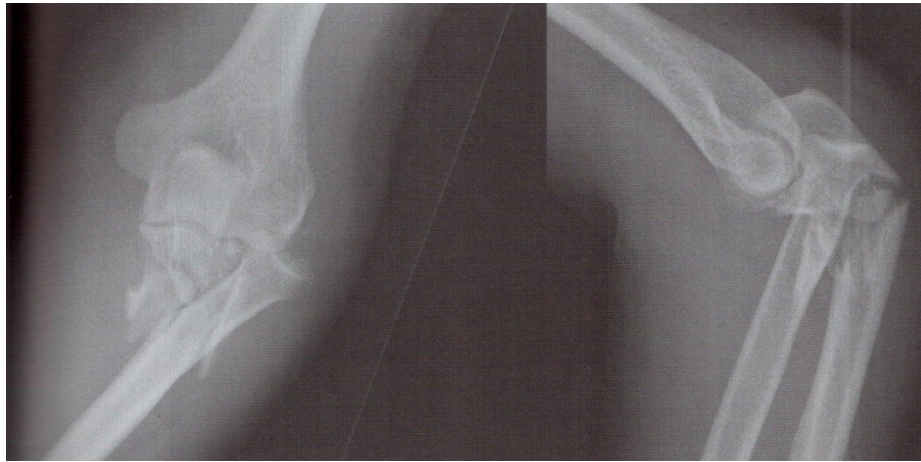


Case based discussion



A 23 year old while on a night out fell onto his left hand and has come to casualty with pain and deformity. Describe the X-ray.



- How would you manage this patient?
- When would you take this patient to theatre?
- What approach would you use?
- What was the principle behind this repair?

