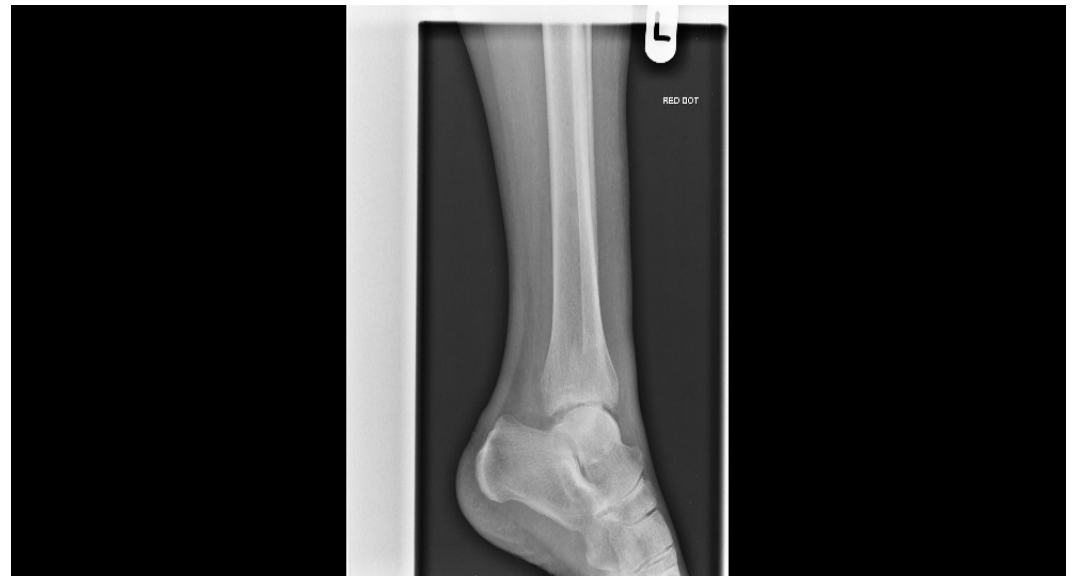
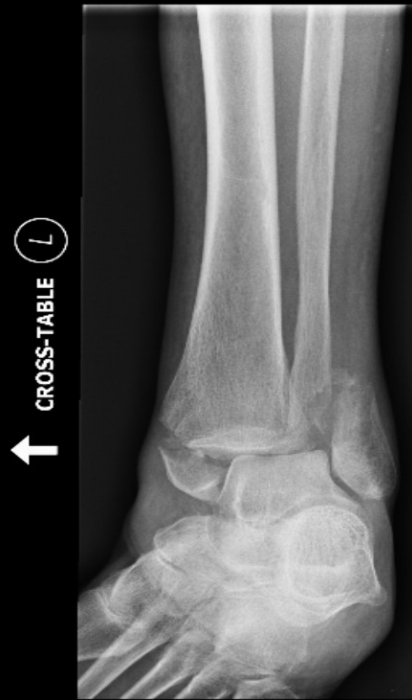
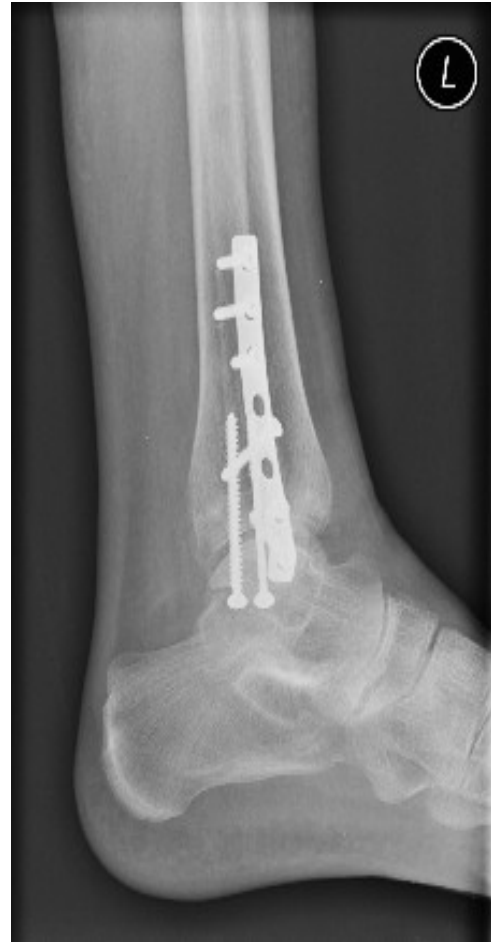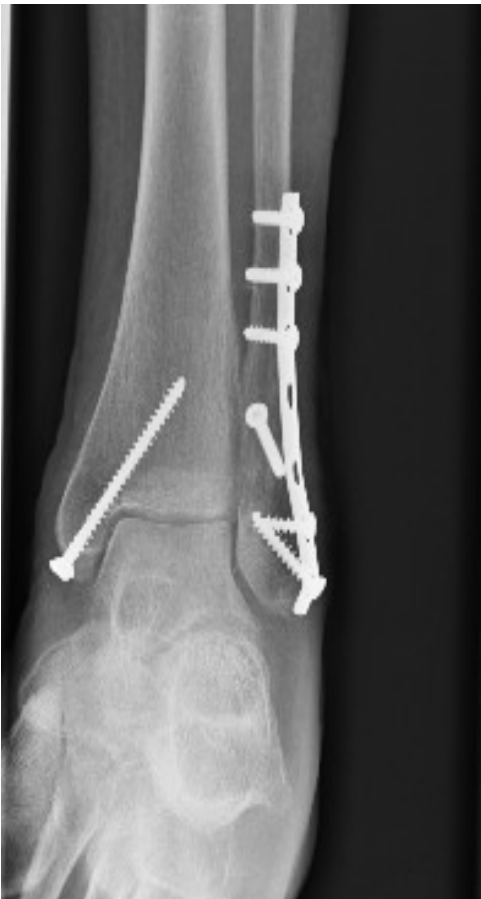63 yr female old open #



Describe injury

Initial Management?

Plan



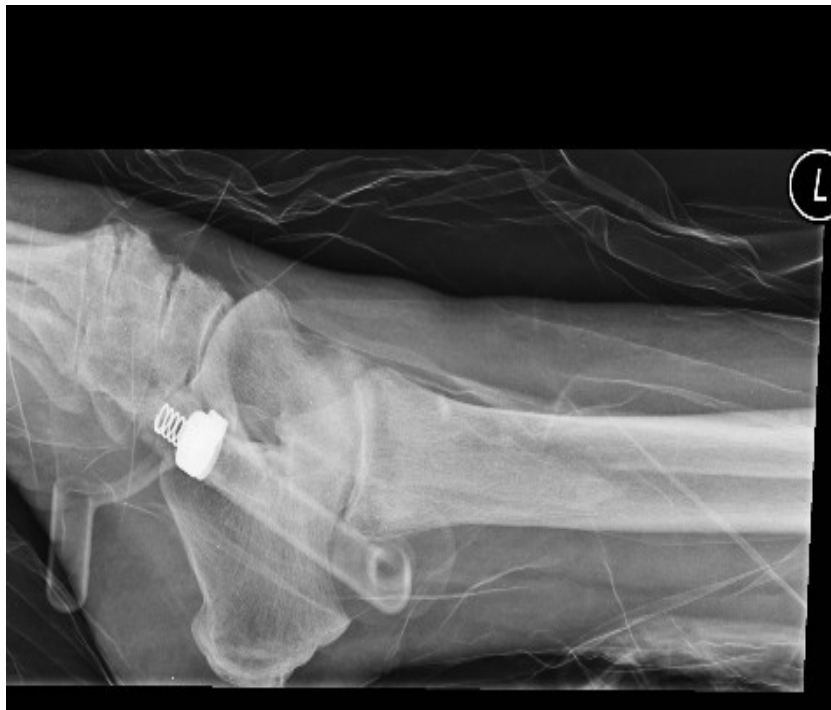Ramsey and Hamilton
(JBJS (B) 1976)
1mm lateral shift of the
talus in the ankle
mortise
reduces the contact
area by 42%

What plate is
used?

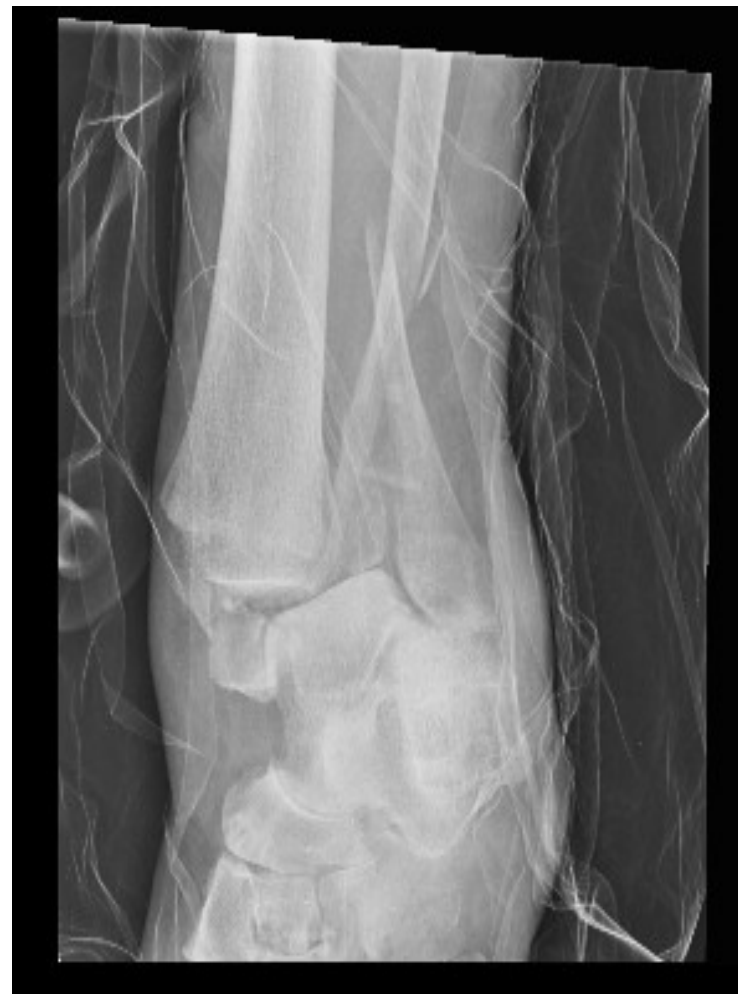What is plate's
function (in this
ORIF) ?

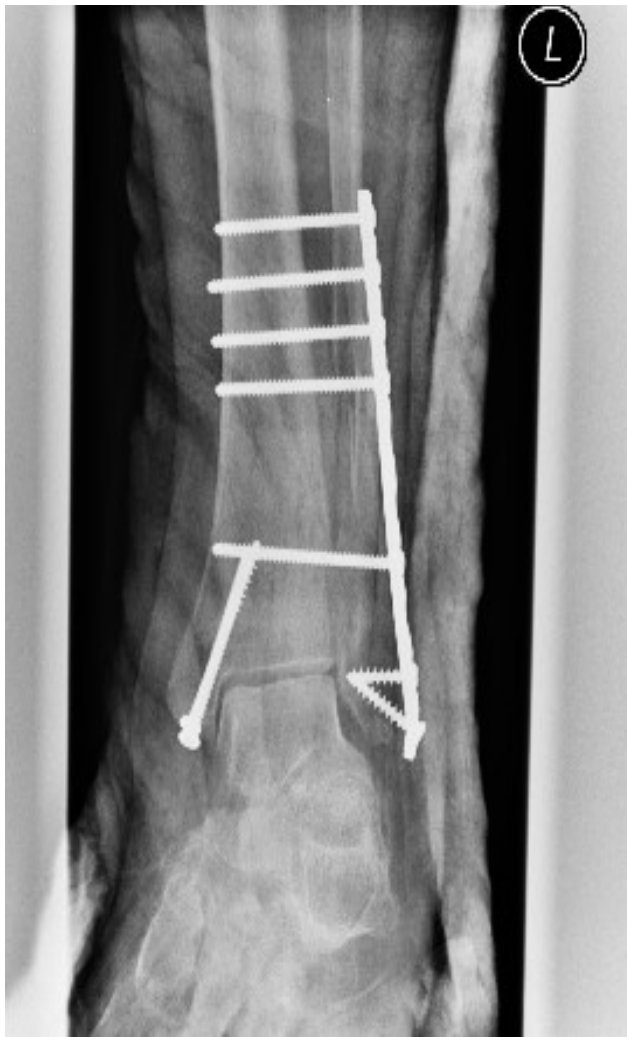Post Op plan ?

89yr women,
osteoporotic



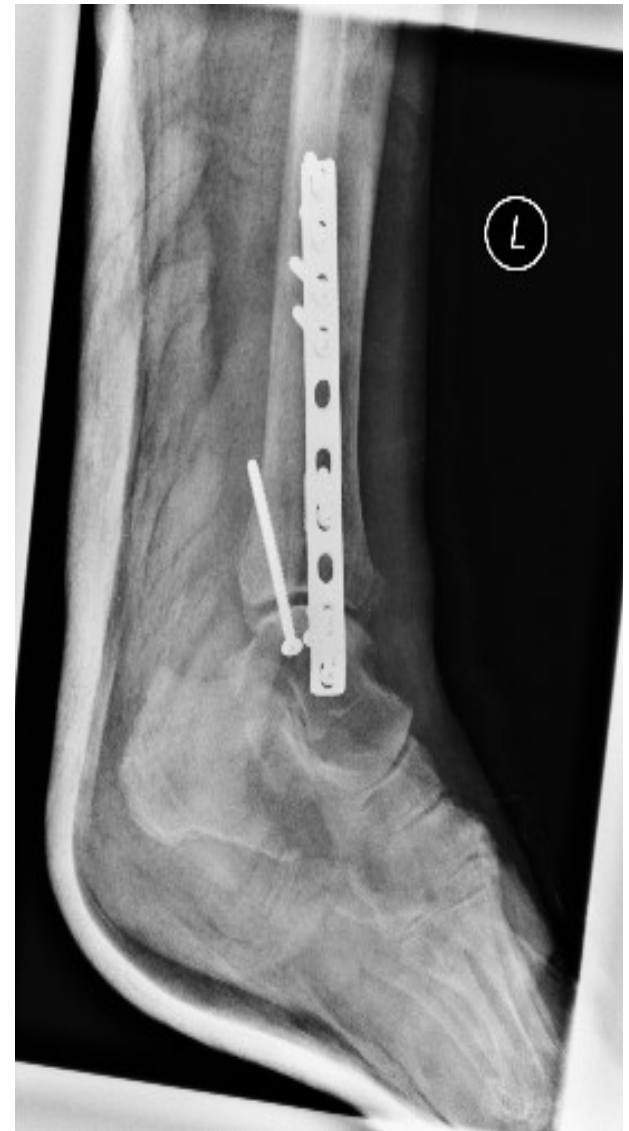Describe injury
Plan & Concerns?





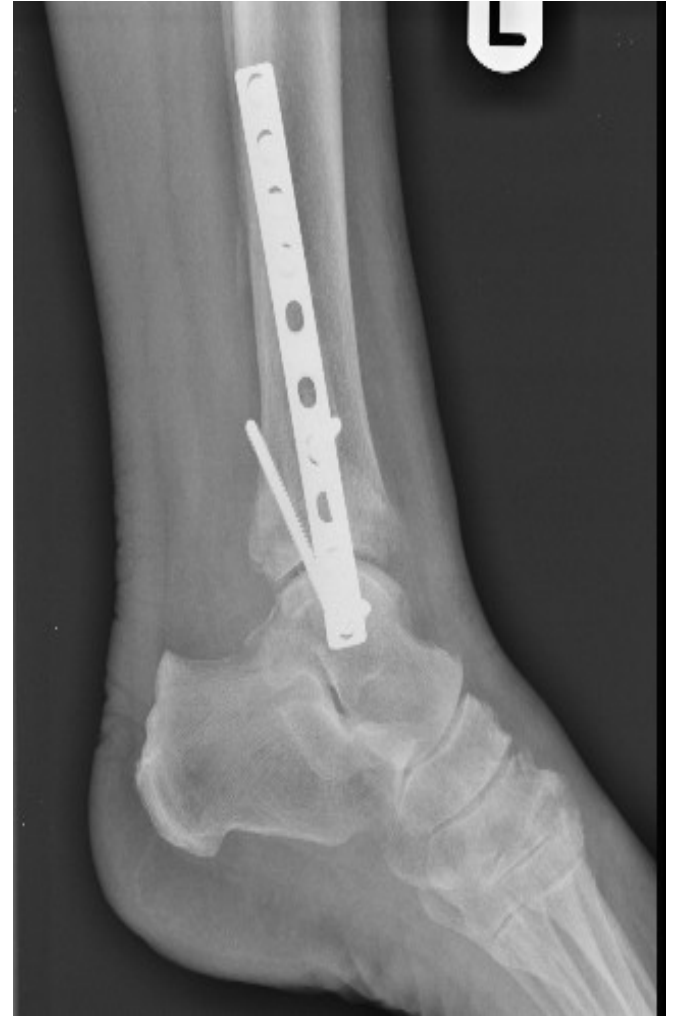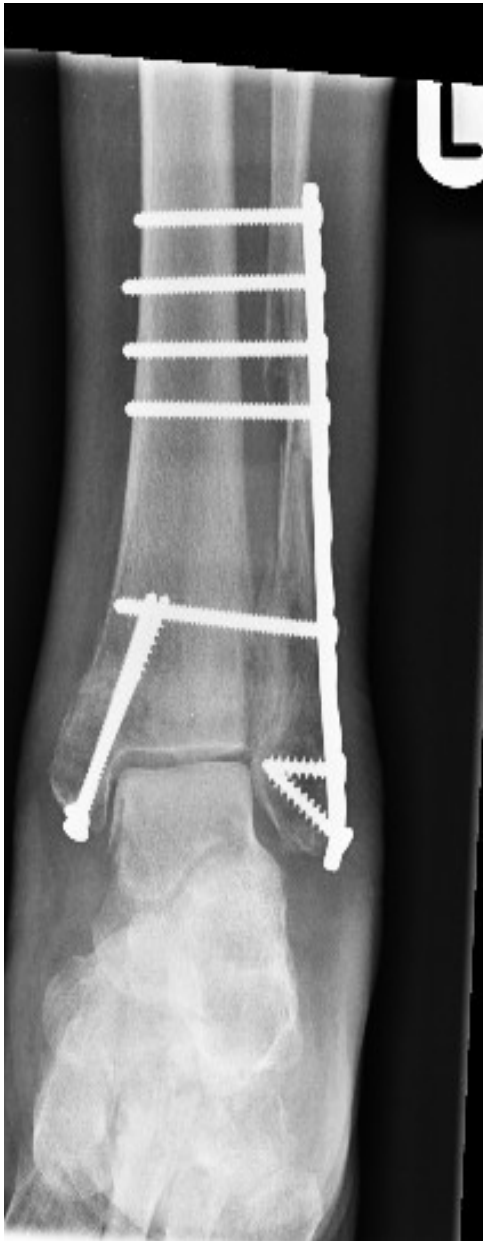What plate is used?

What is plate's function (in this ORIF) ?



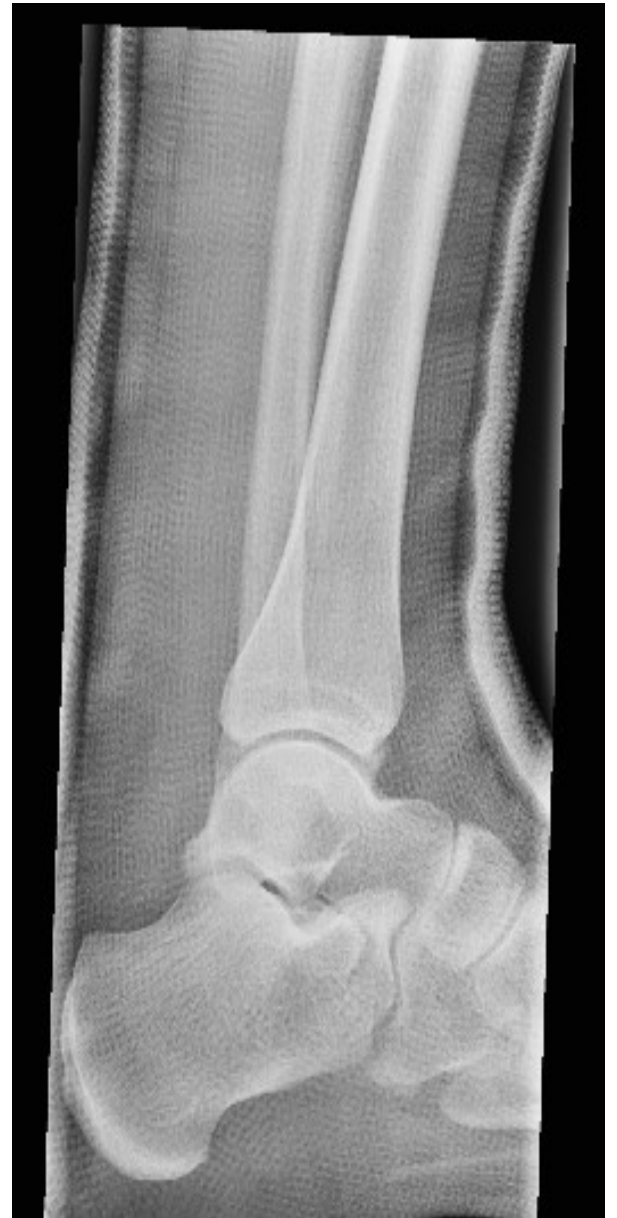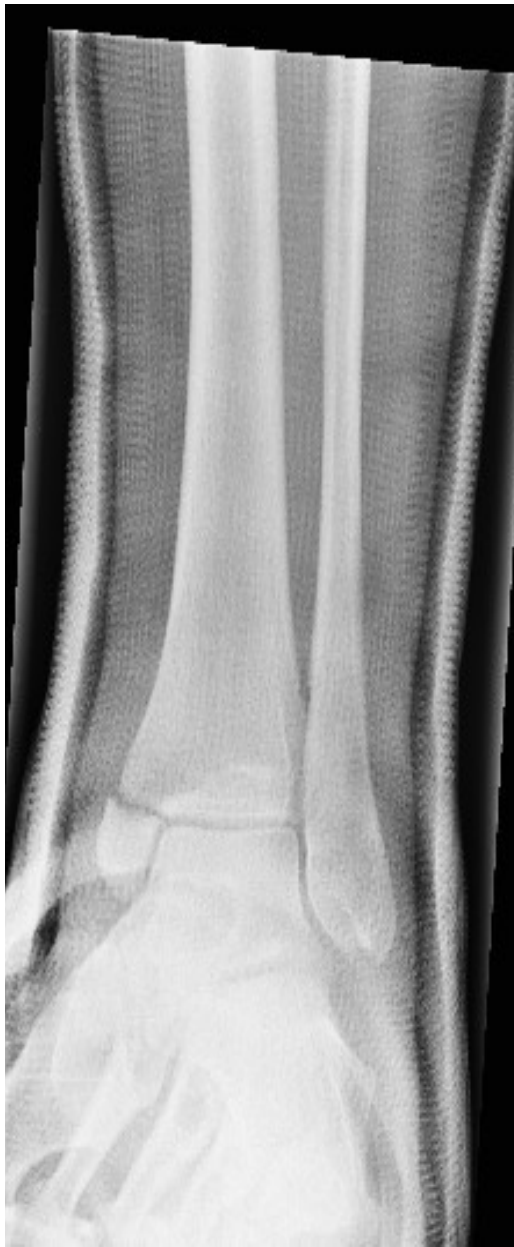How can plates be used?

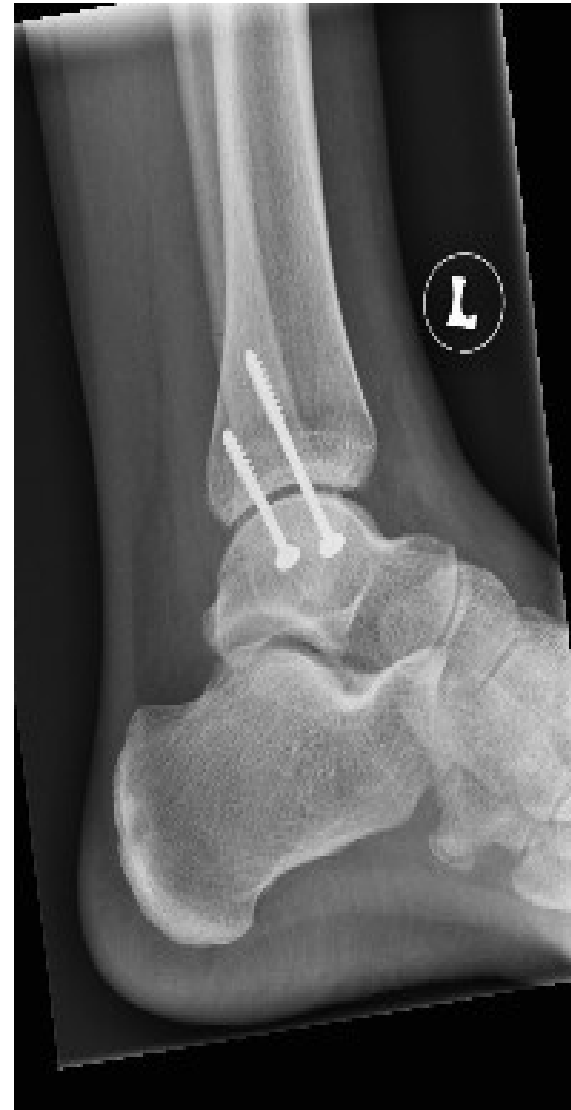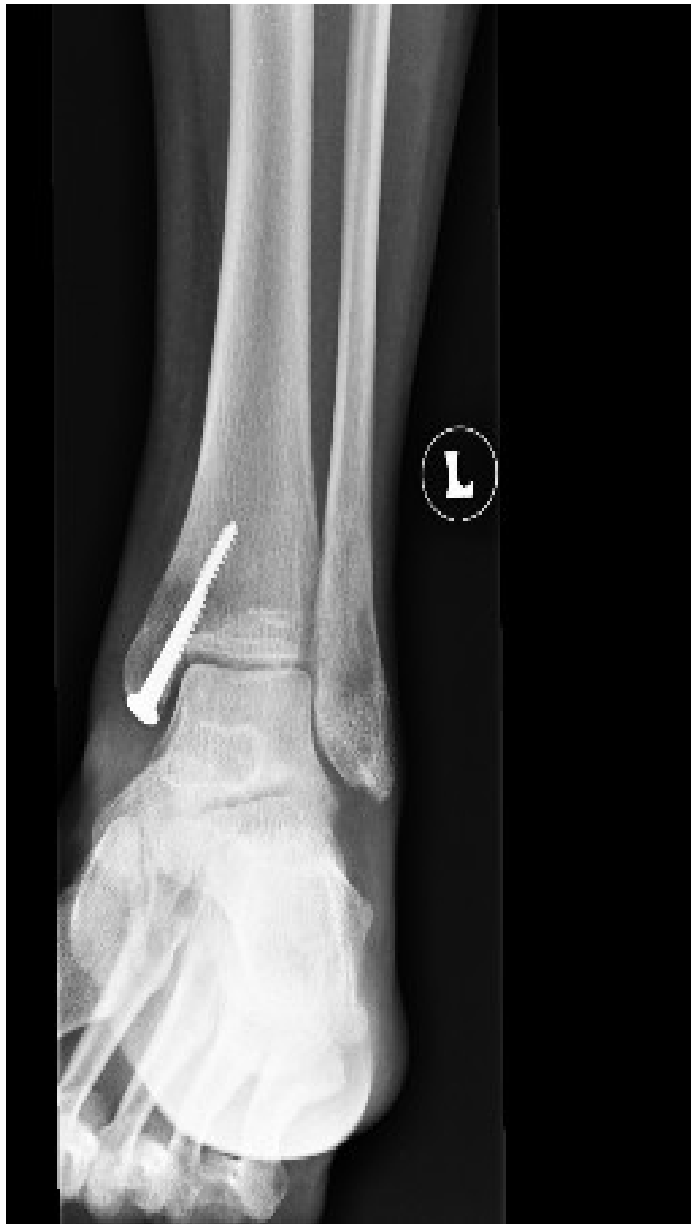+ 6/52, out of POP



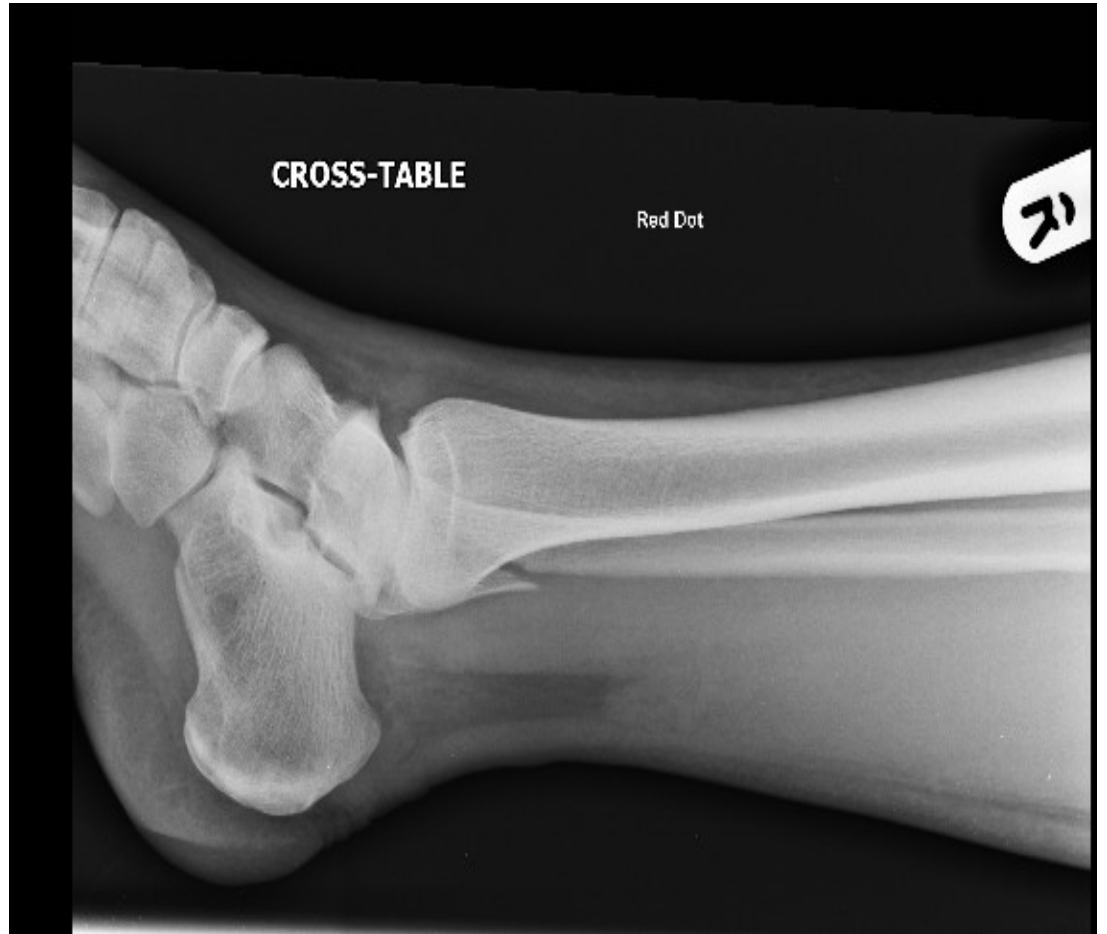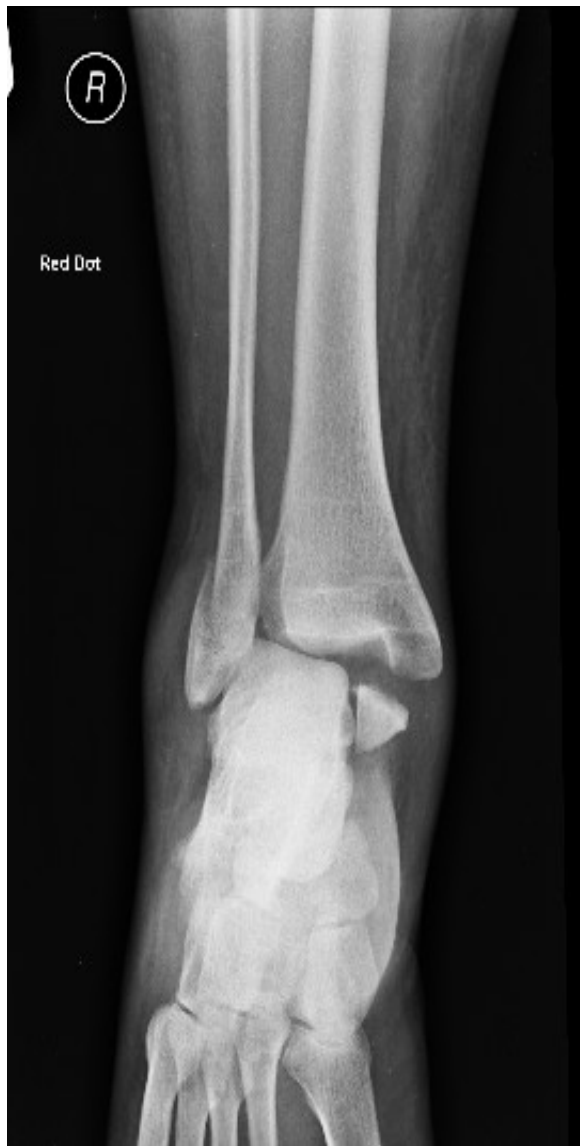23 old female climber

Describe
Management plan

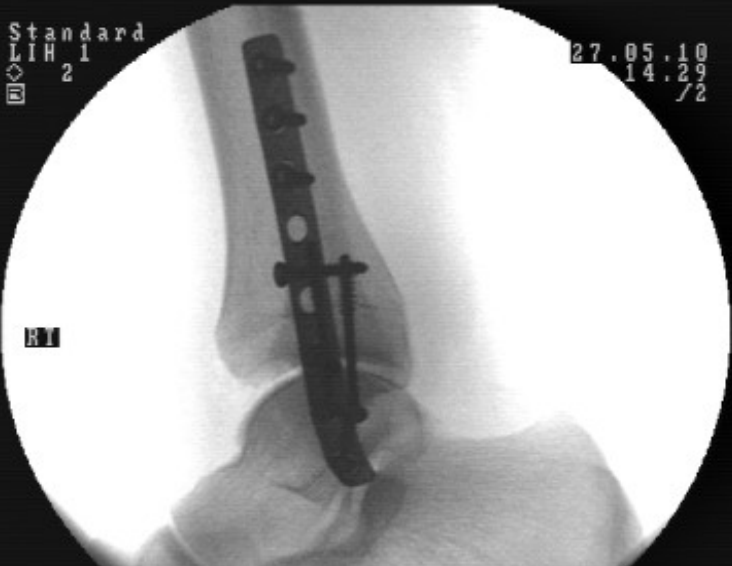
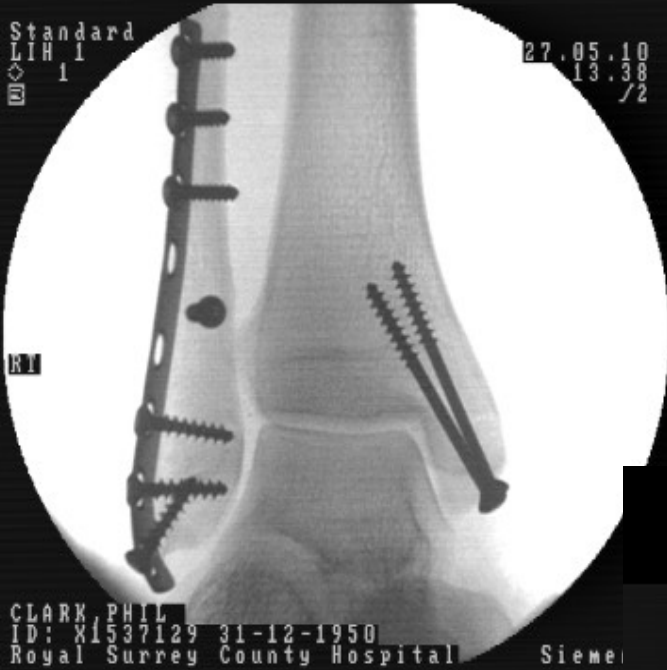


60yr man.



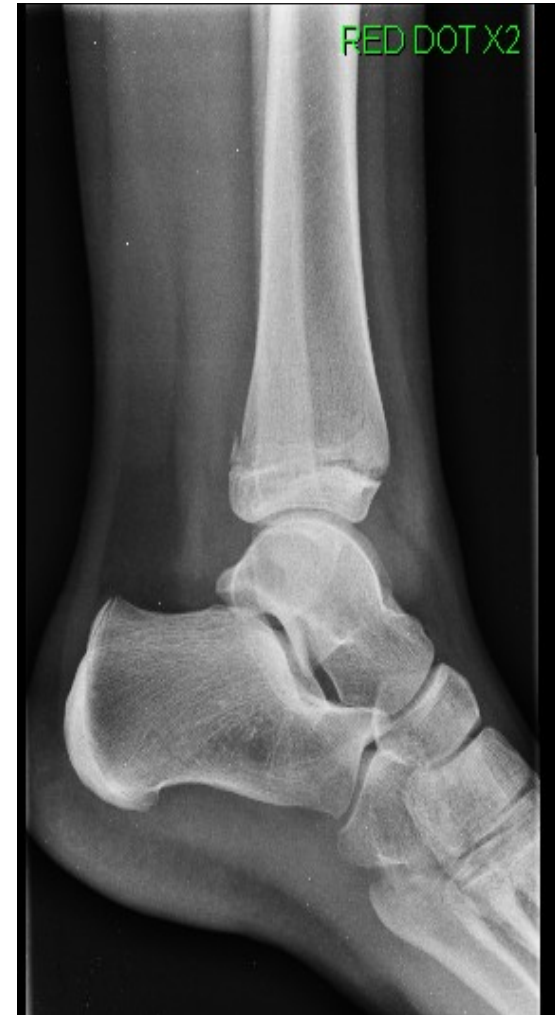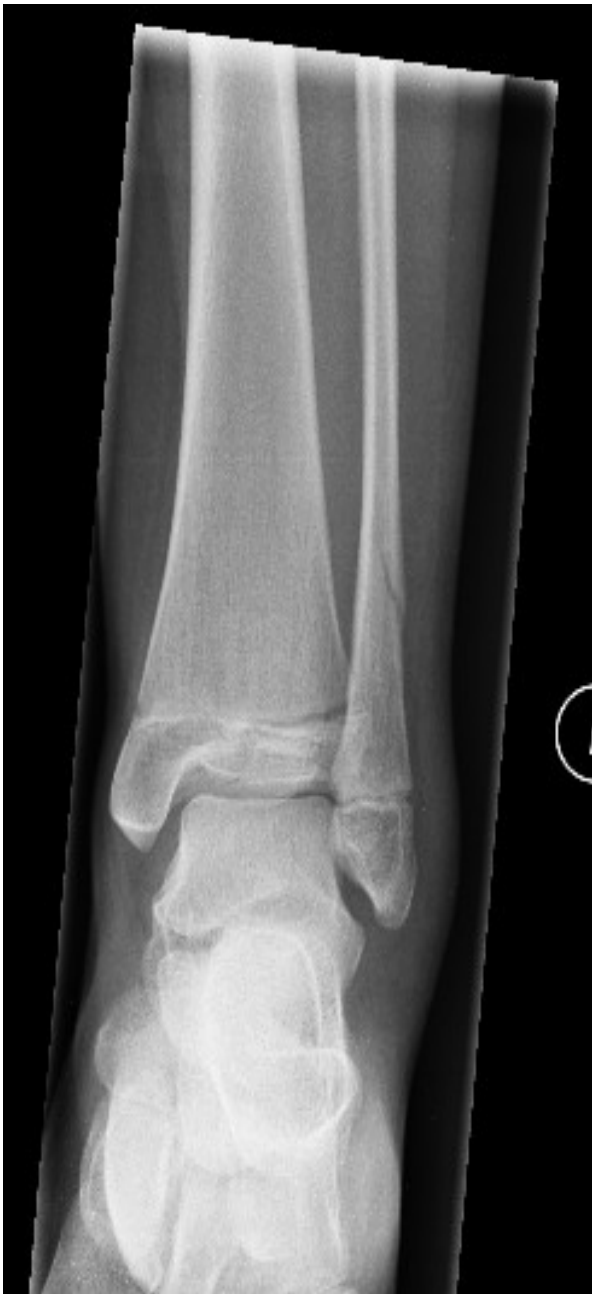Diastasis stable on table



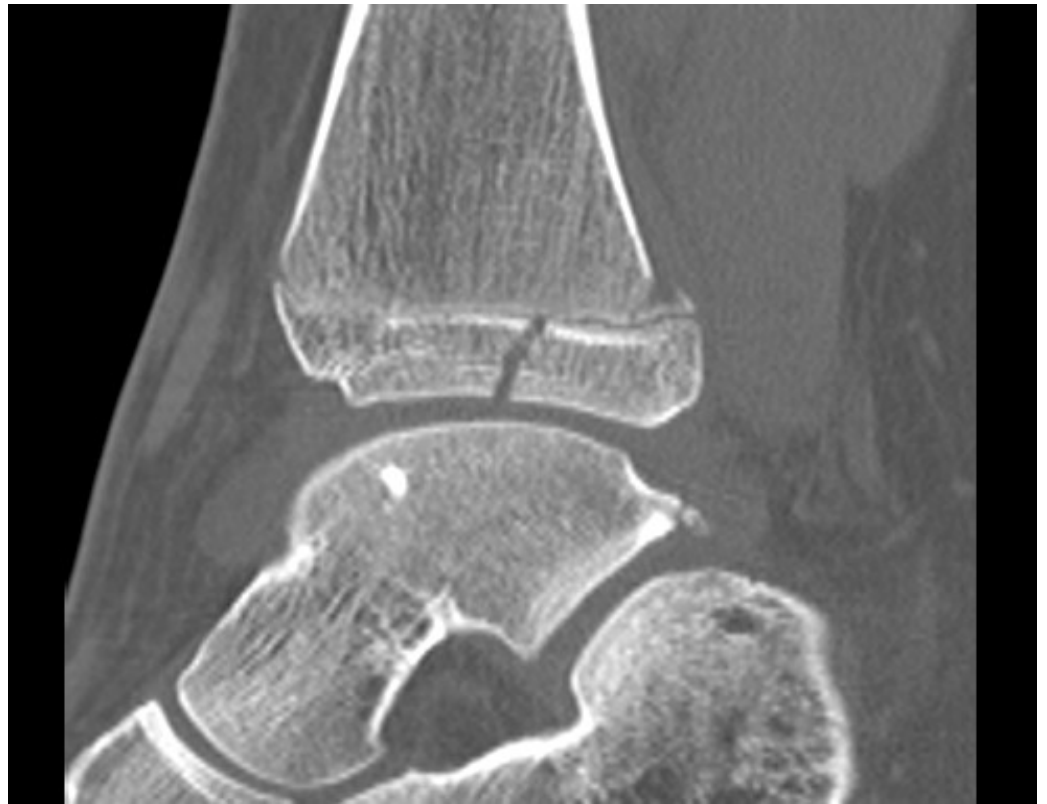
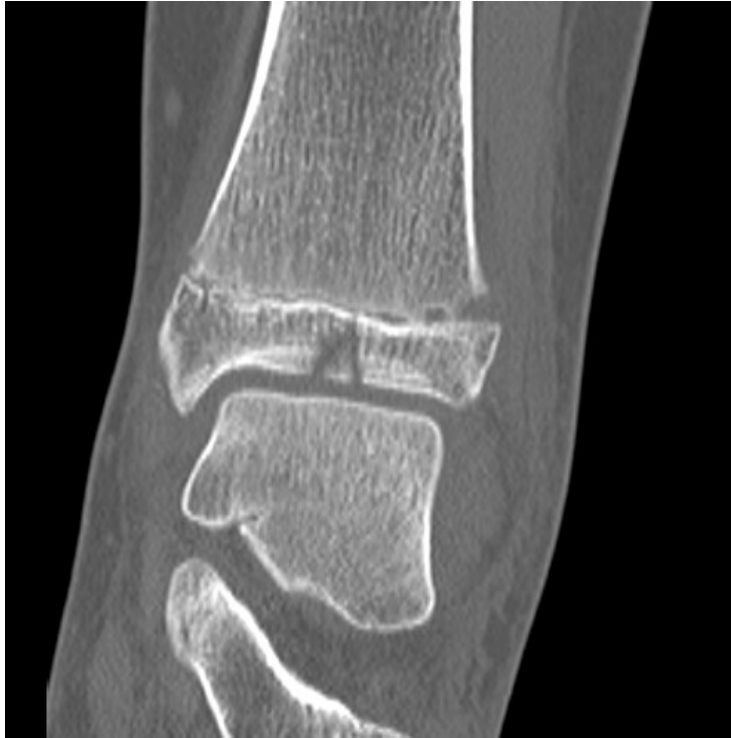Methods of checking diastasis?

14 yr girl.
Management

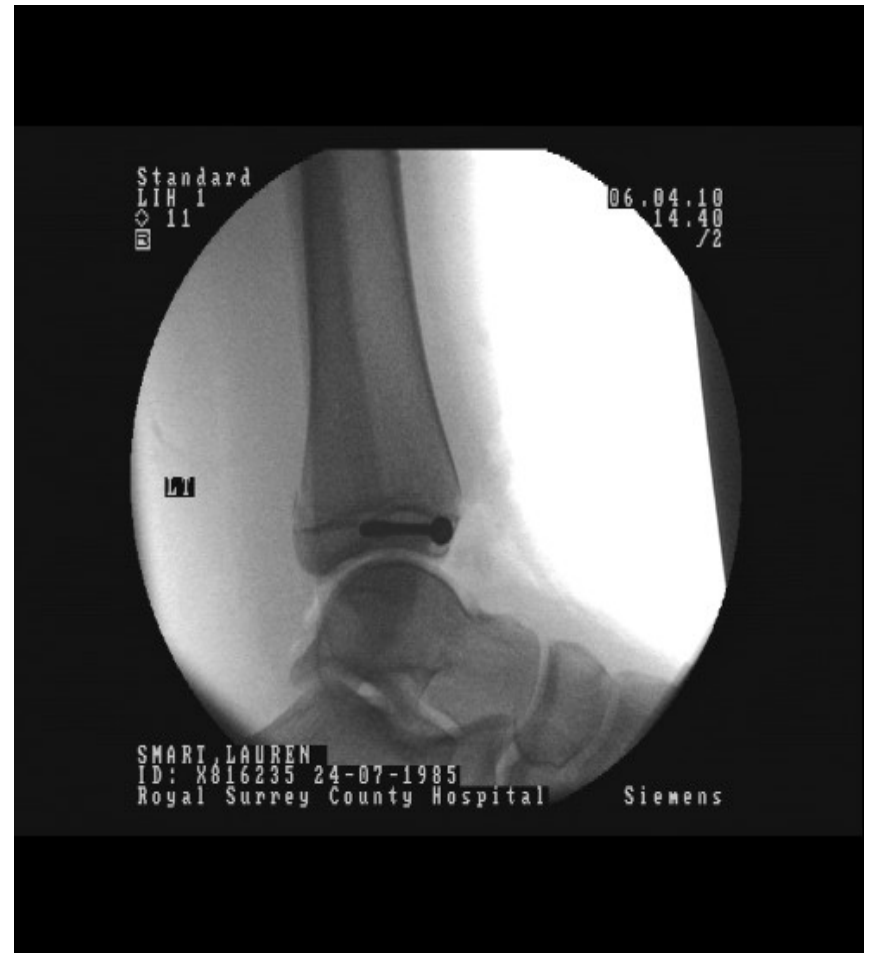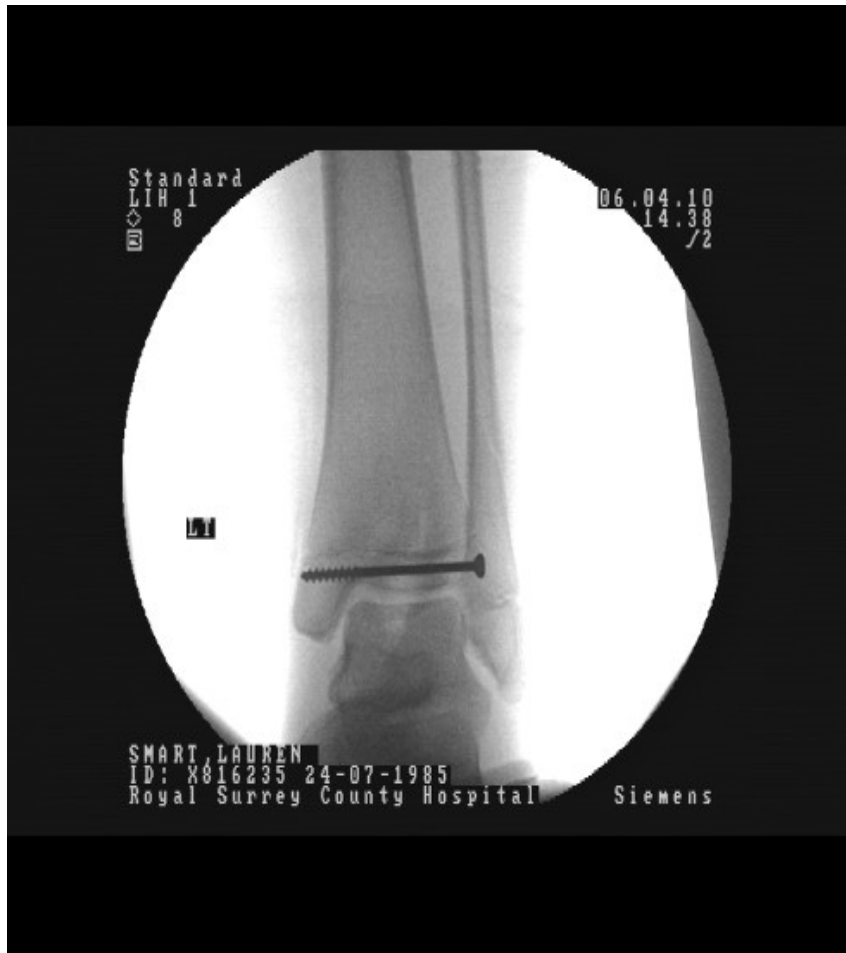Describe &
initial management



Describe with CT
Plan

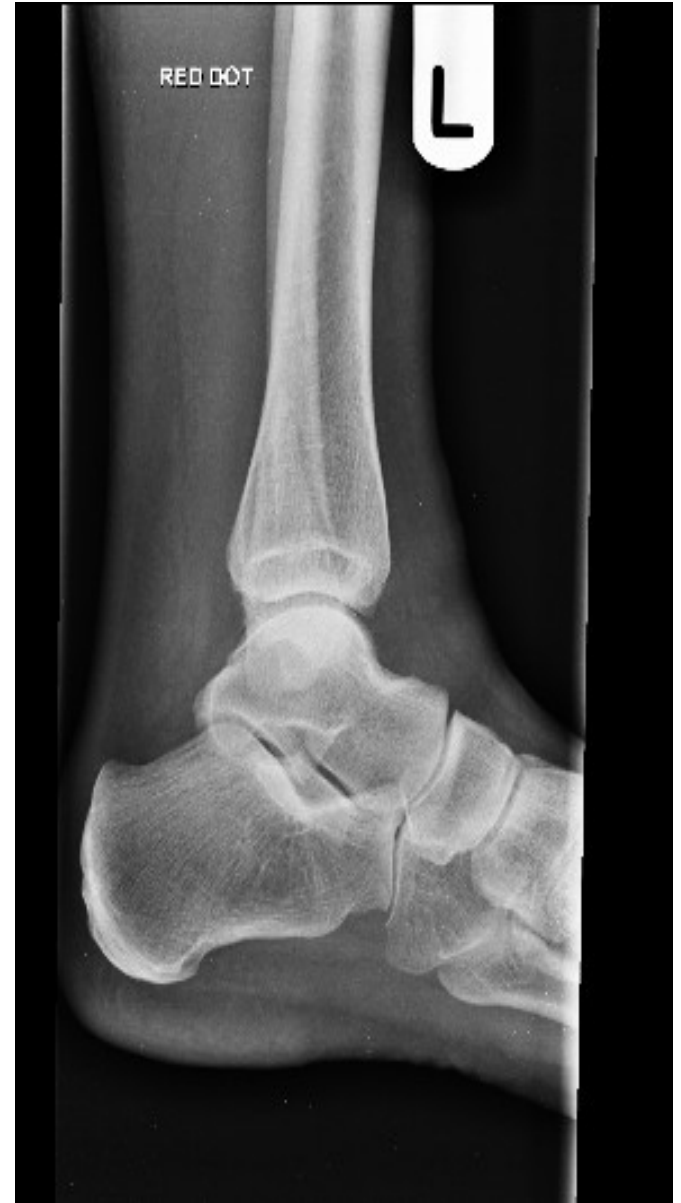
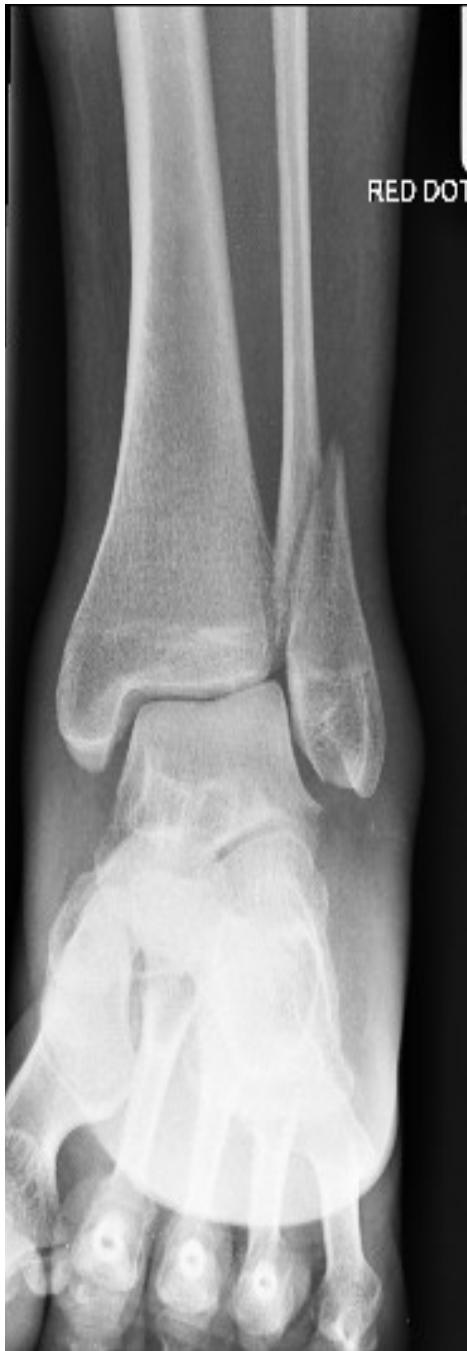
14 yr old girl – intraop II images

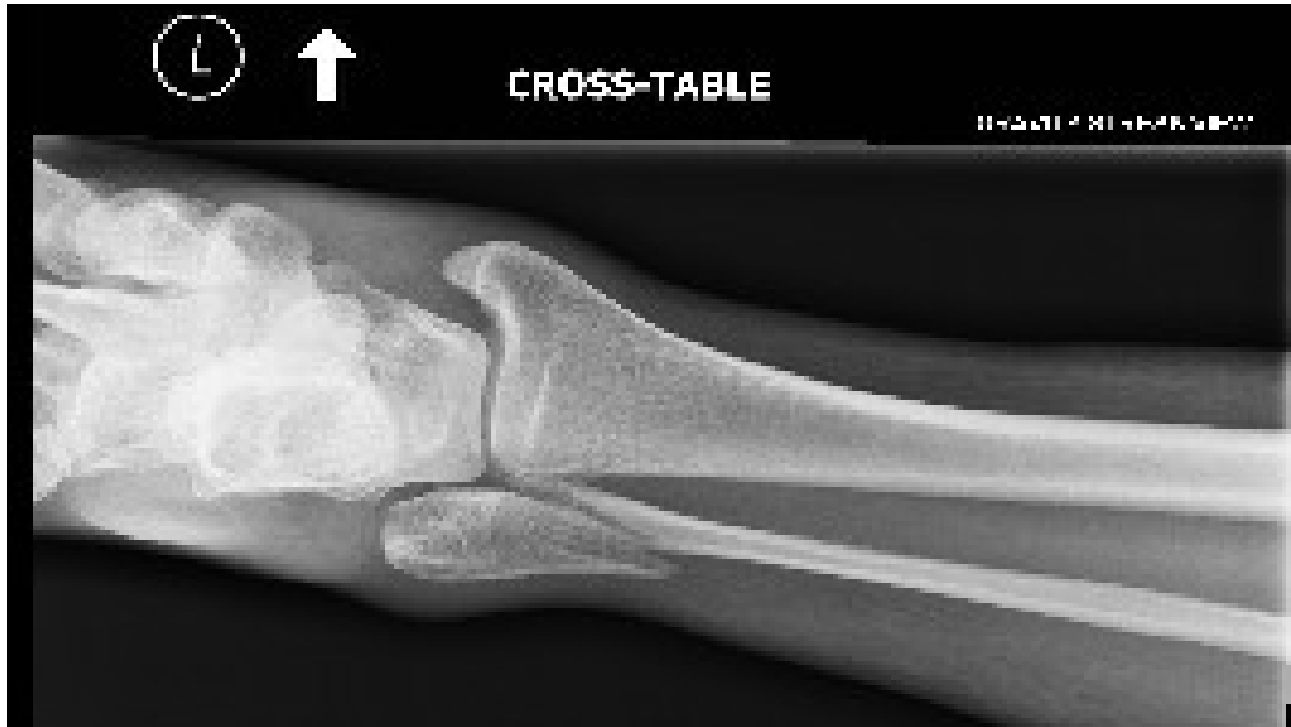

65 yr female

Operative or
Non – Operative
management?



Gravity Stress View



The use of gravity or manual-stress radiographs in the assessment of supination-external rotation fractures of the ankle

H. J. Schock, M. Pinzur, L. Manion, M. Stover

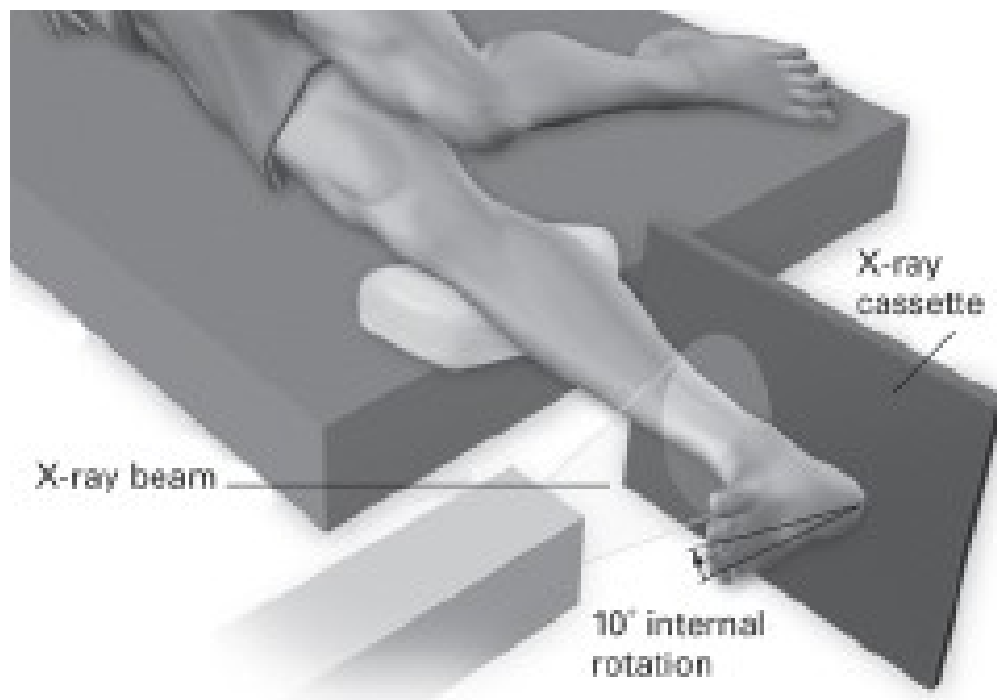
J Bone Joint Surg Br August 2007 89-B: 1055-1059

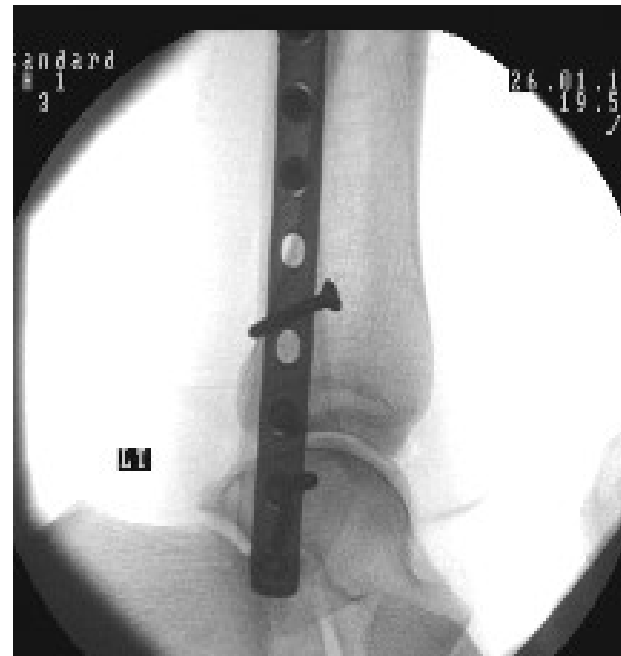
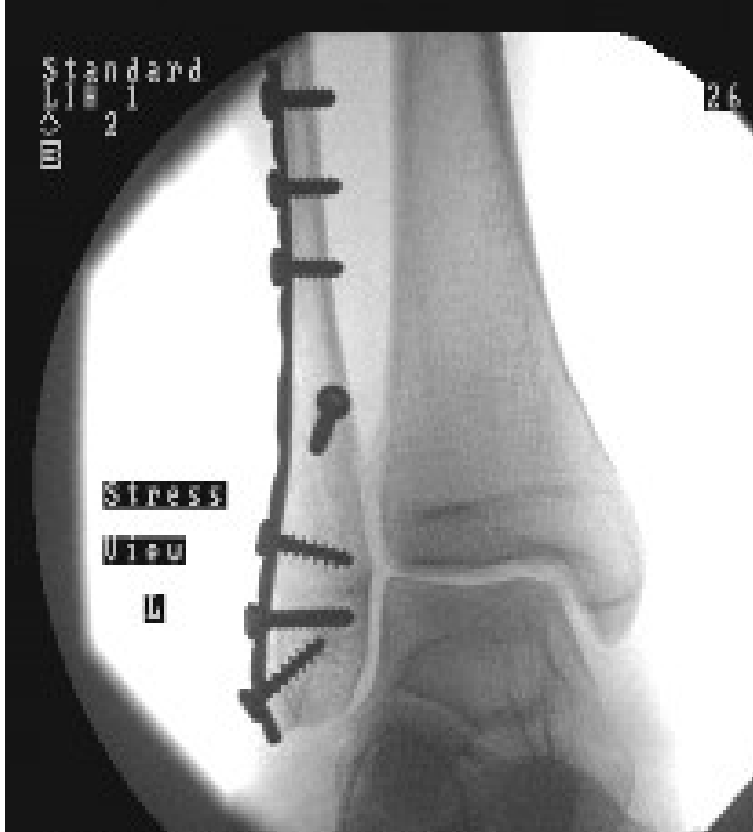
The use of gravity or manual-stress radiographs in the assessment of supination-external rotation fractures of the ankle

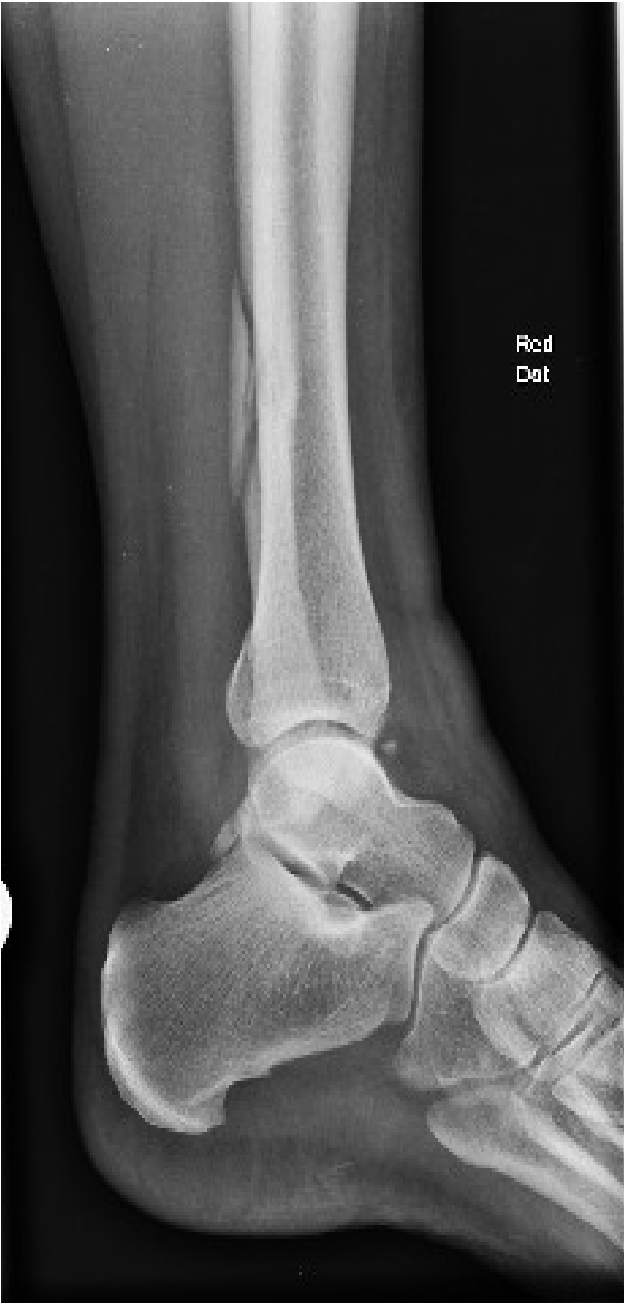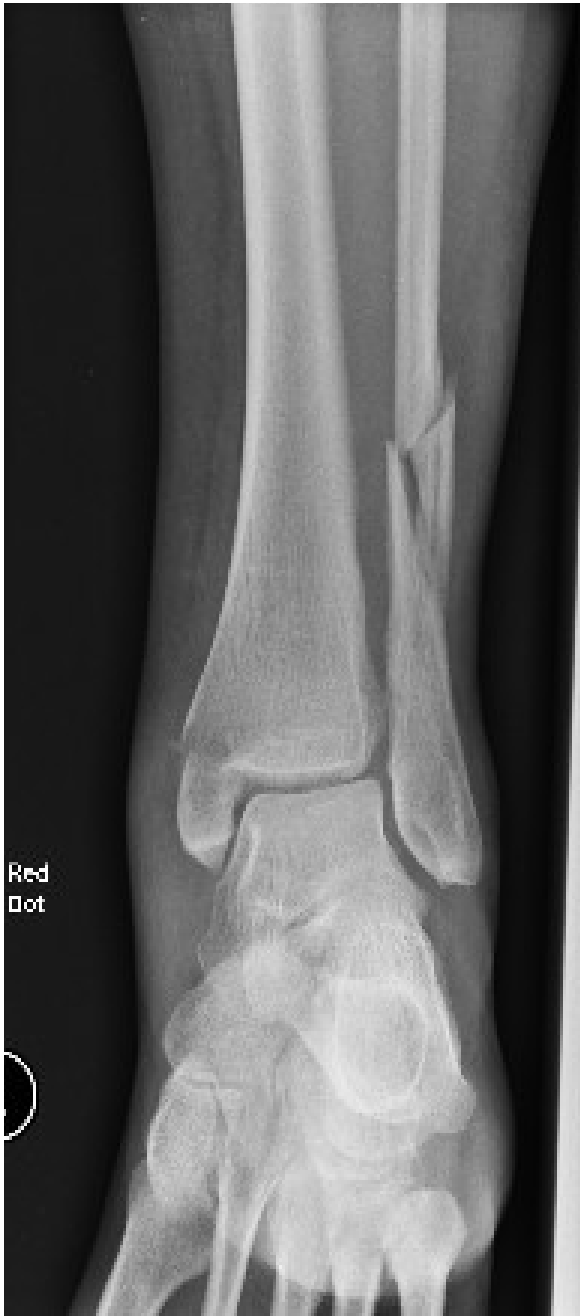H. J. Schock, M. Pinzur, L. Manion, and M. Stover

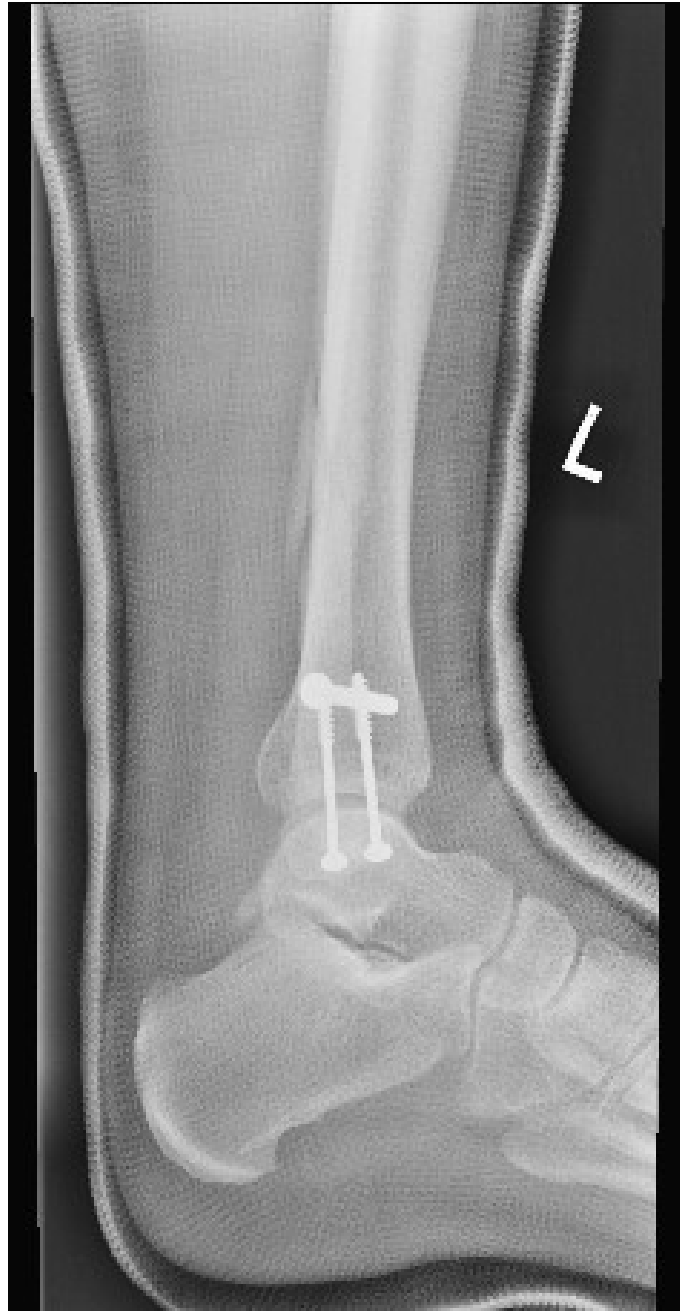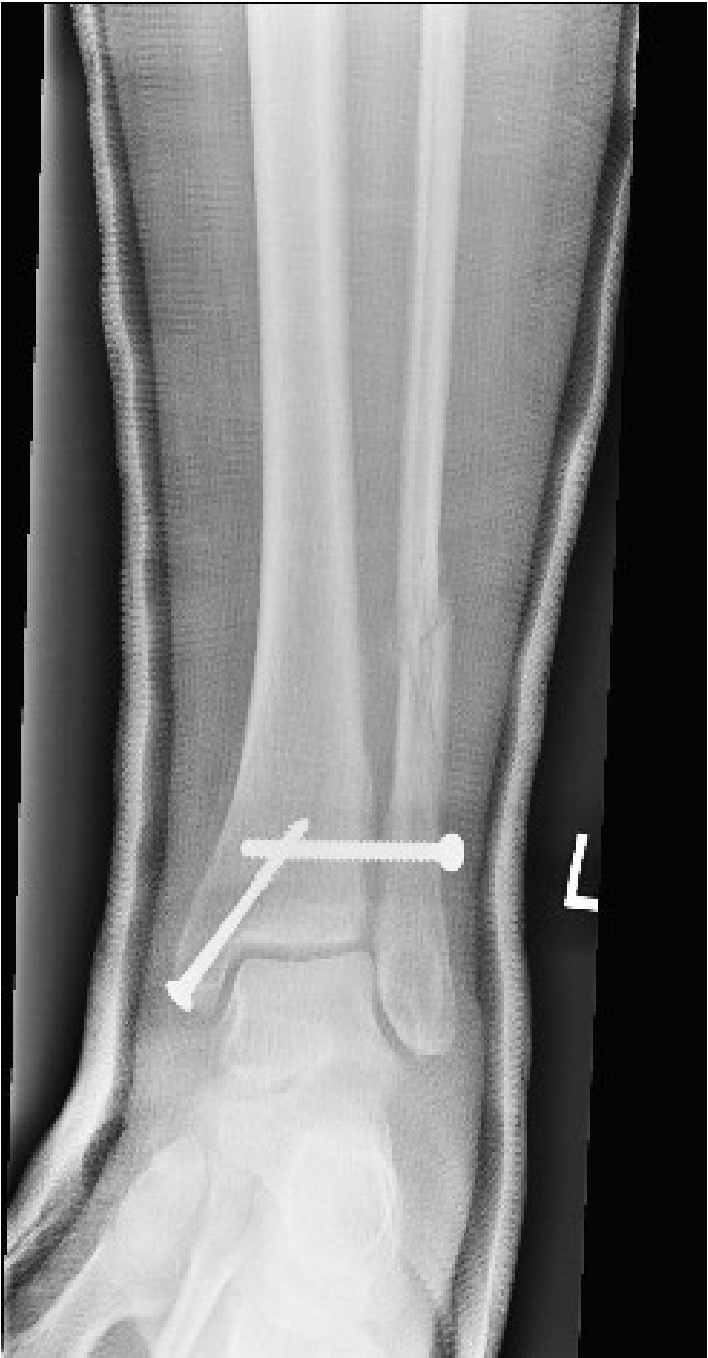J Bone Joint Surg Br, Aug 2007; 89-B: 1055 - 1059.

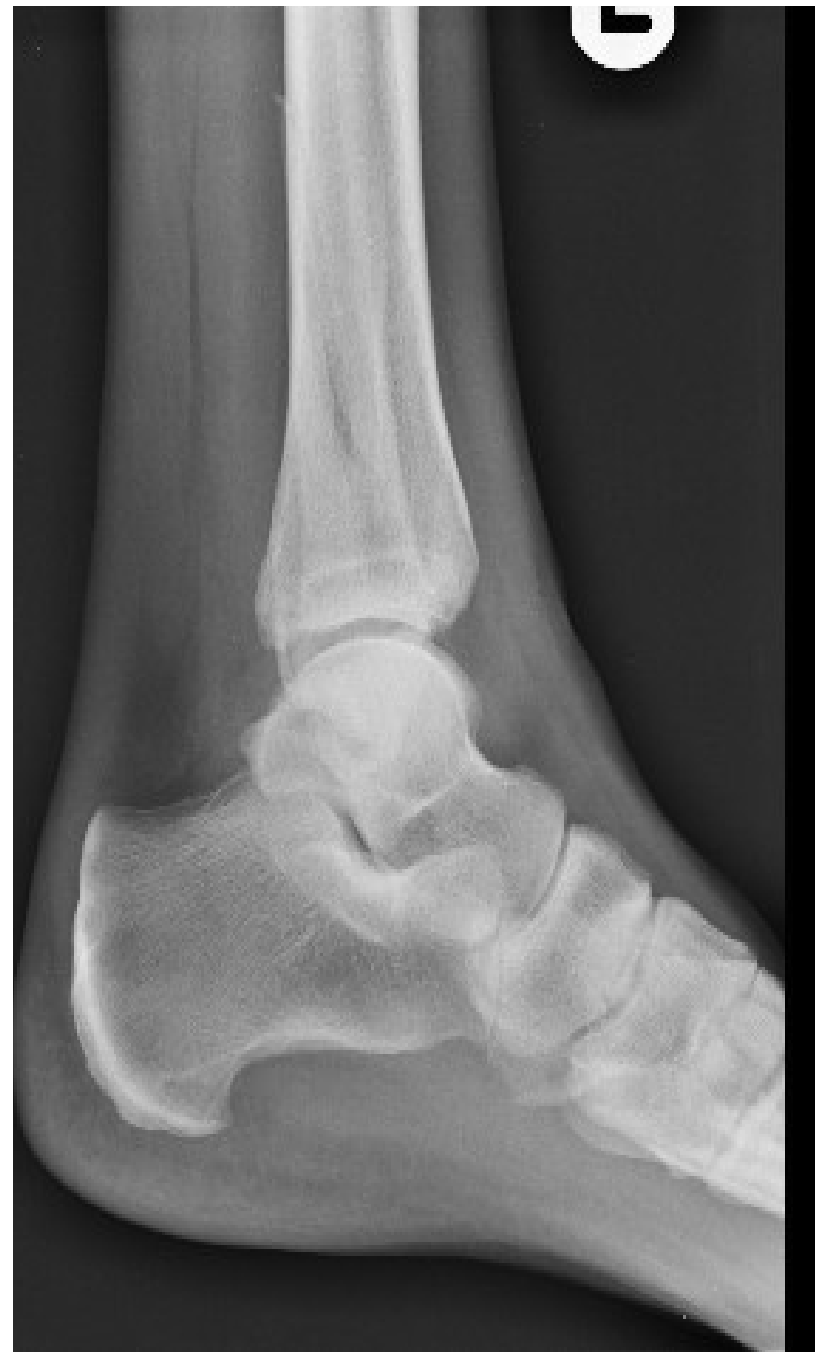
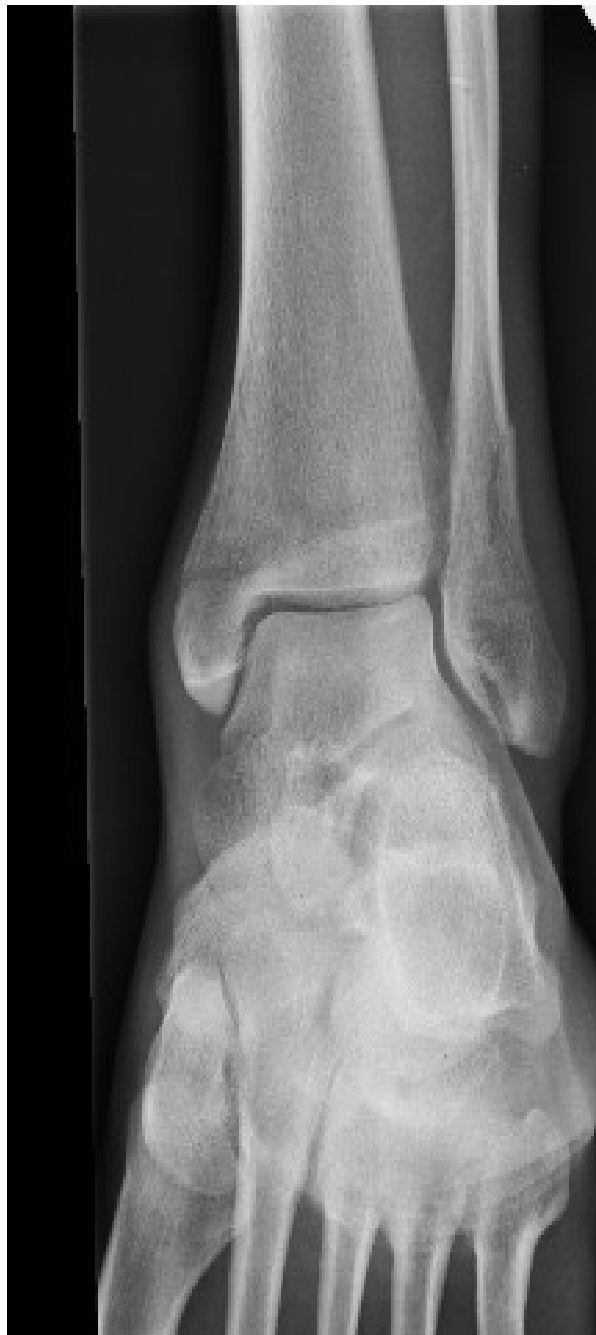


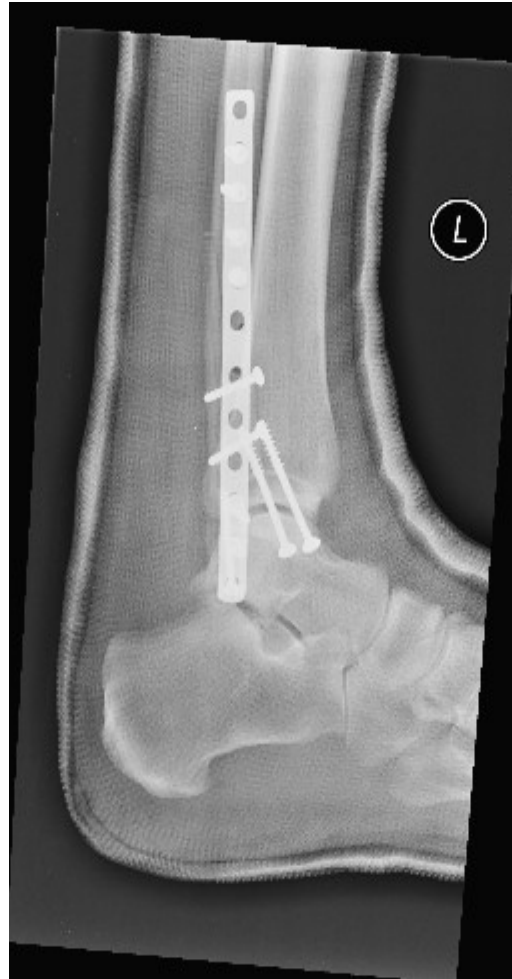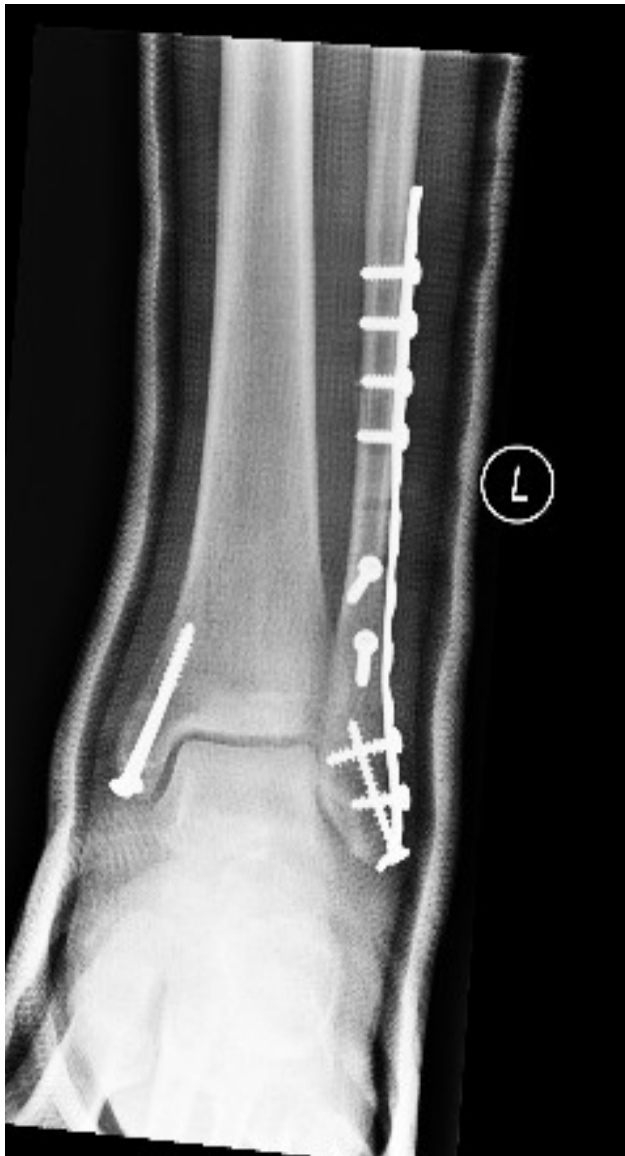48yr female.





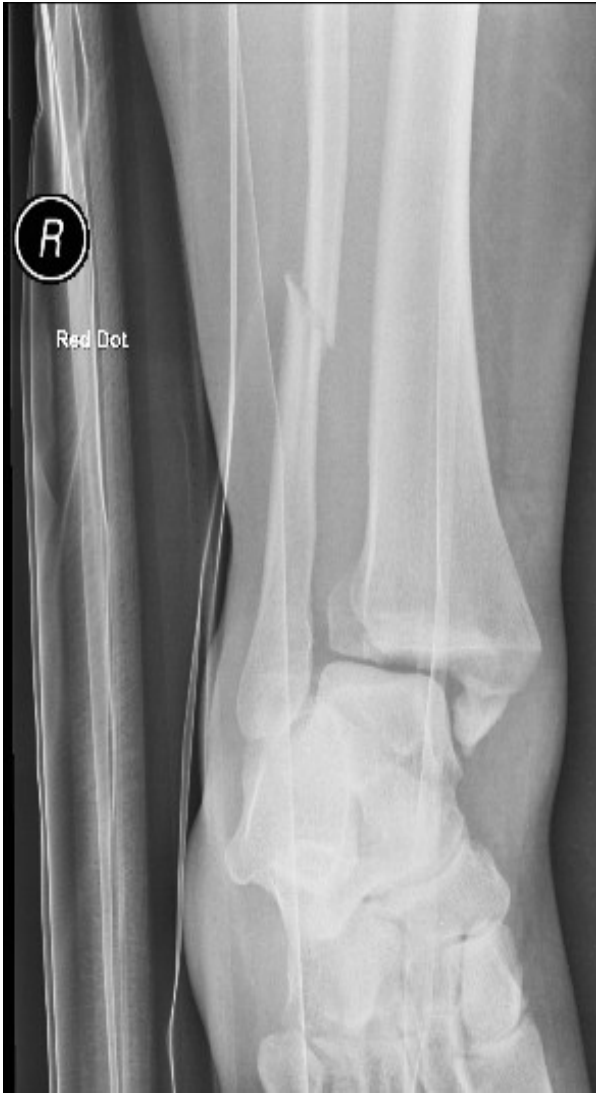
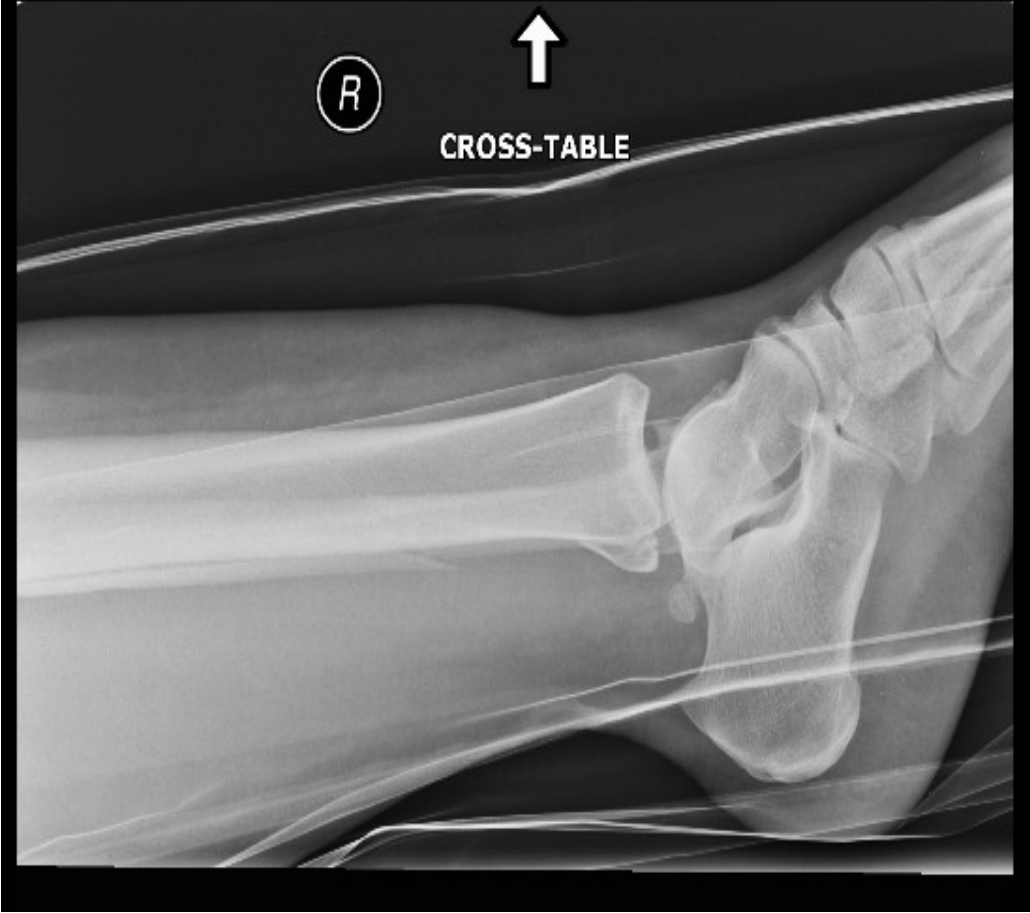
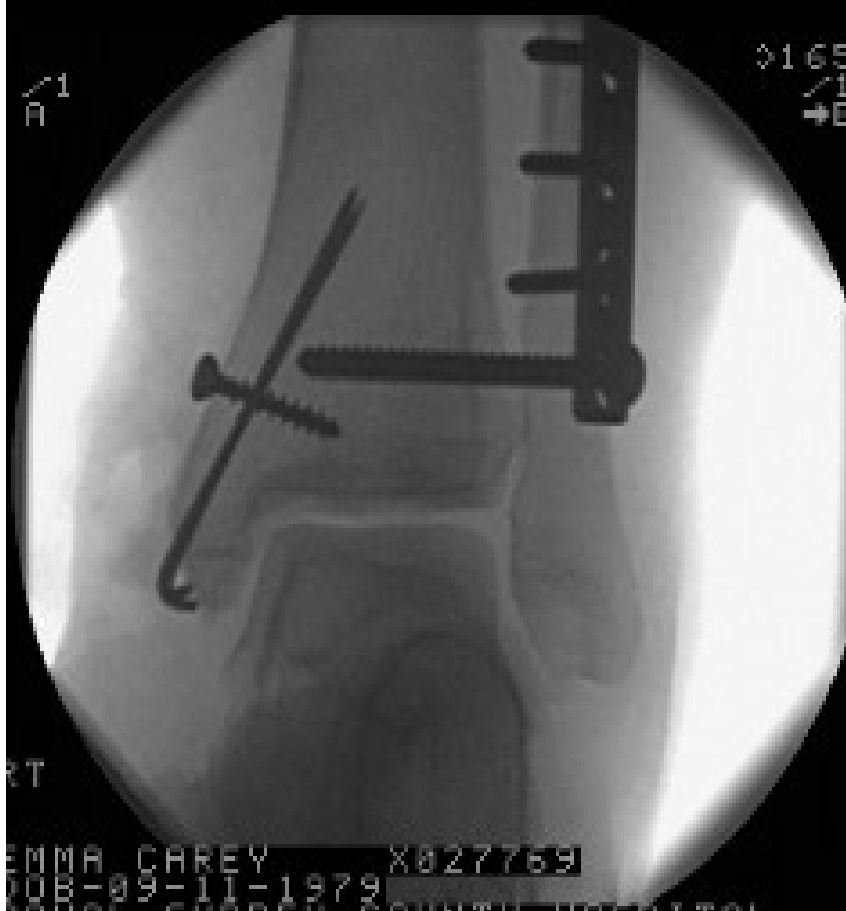Plan surgery 1st...Missed fibula #
going high therefore changed
and used longer plate



34yr female
soccer injury
closed

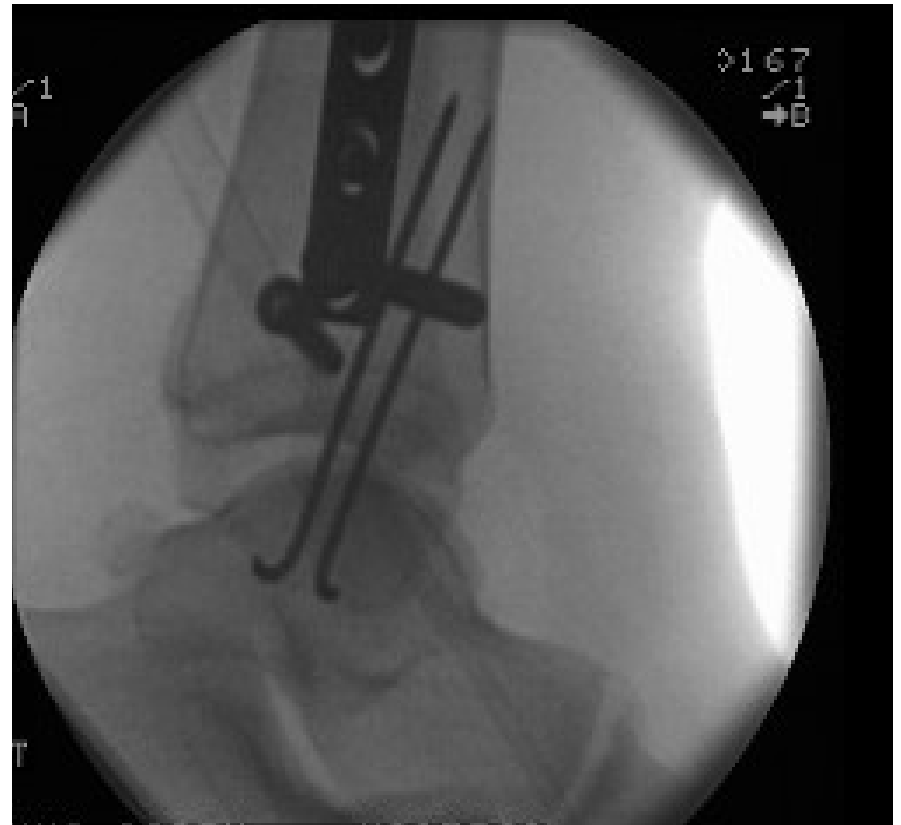Concerns ?



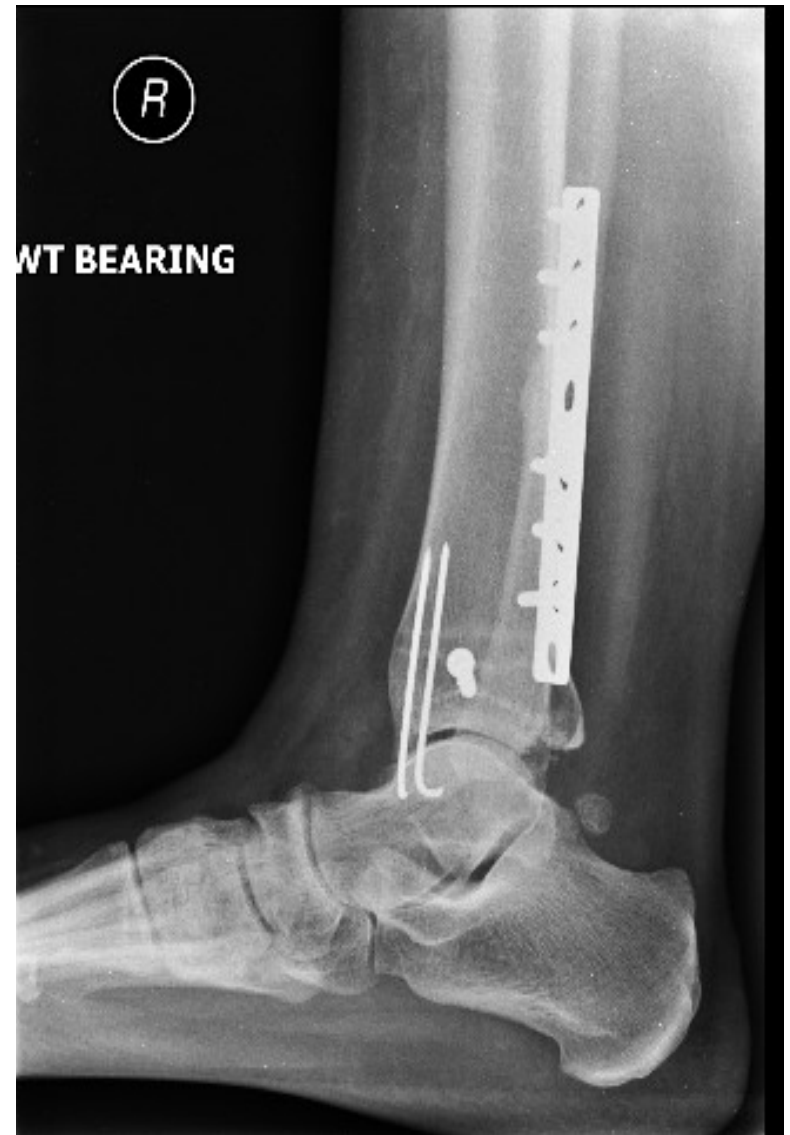
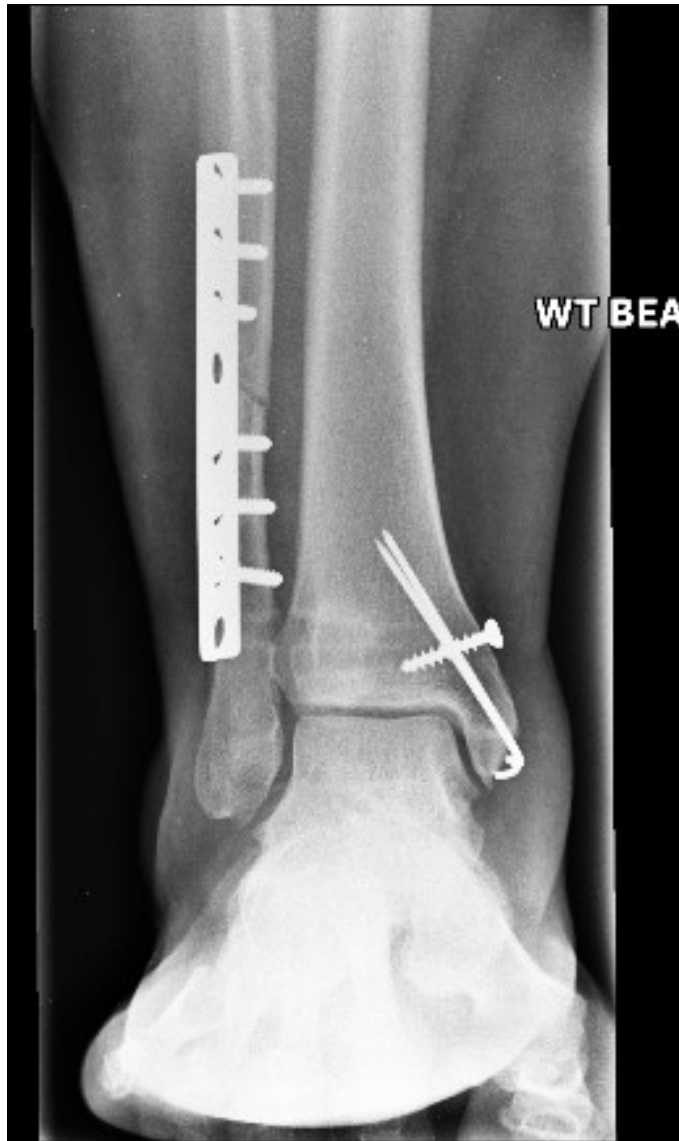
Comminuted
medial
Malleolus

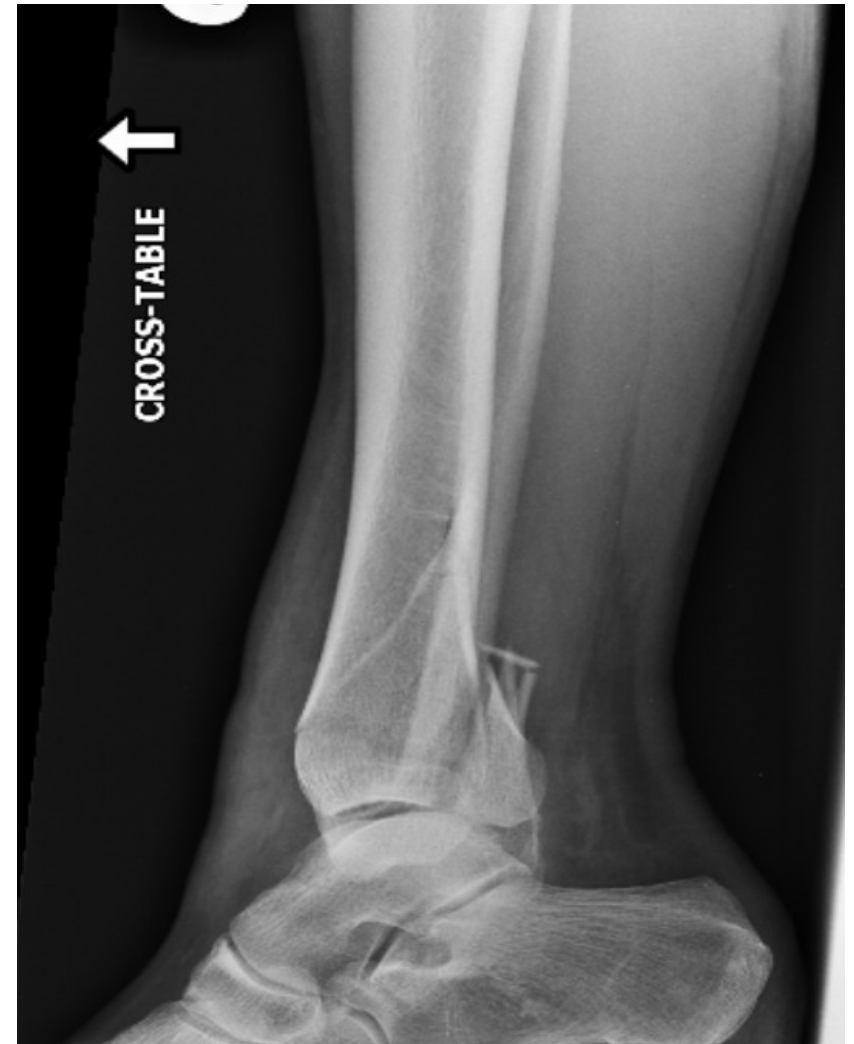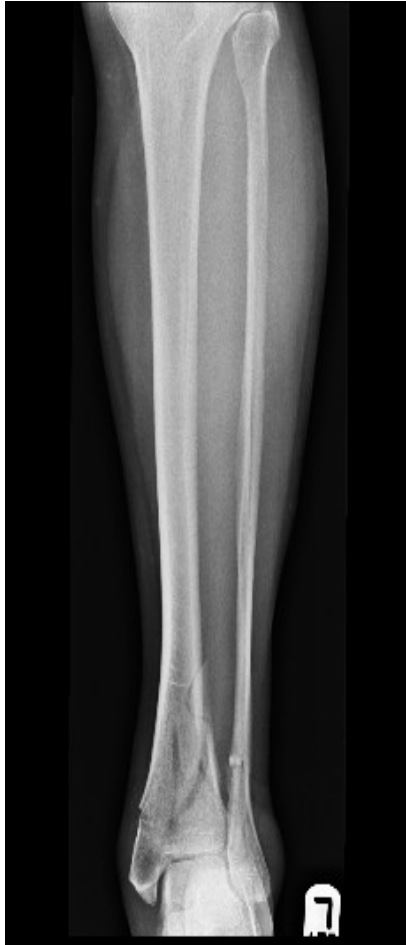Syndesmosis

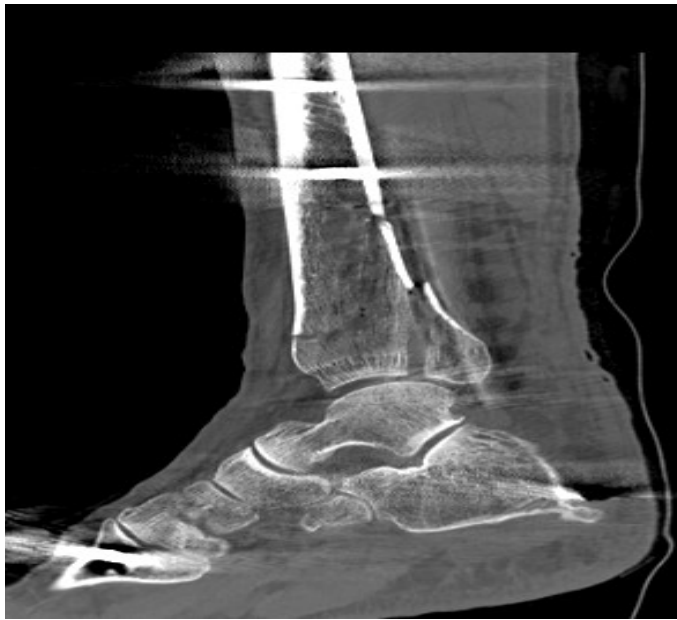


Same girl – after diastasis screw out



70 yr male
fall down stairs





When do you operate?

