

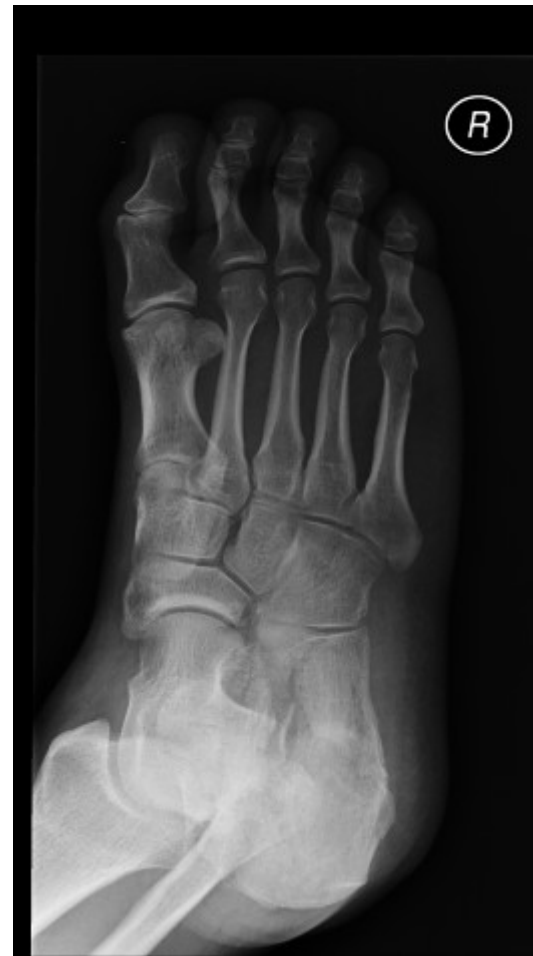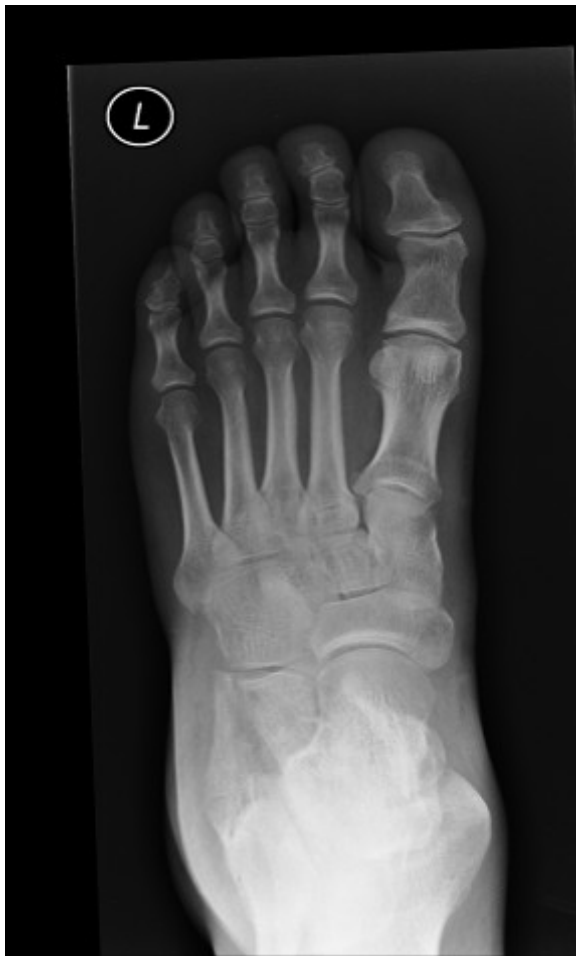Calcaneus Fracture Cases

Sohail Yousaf

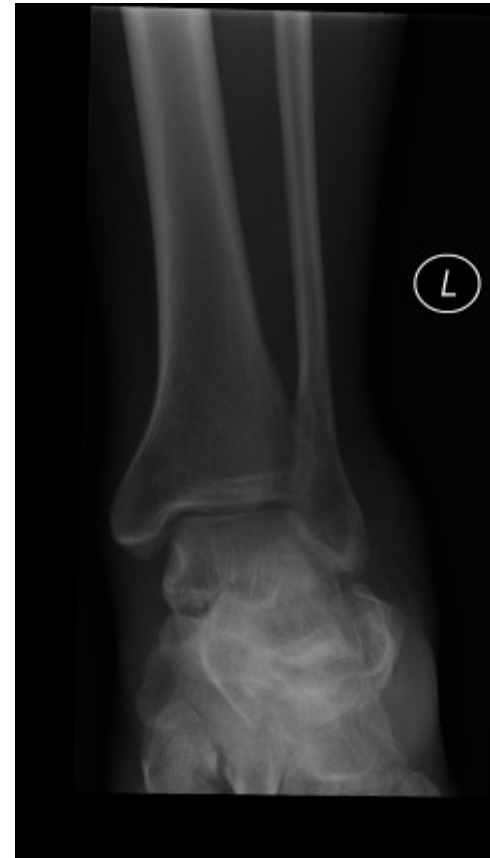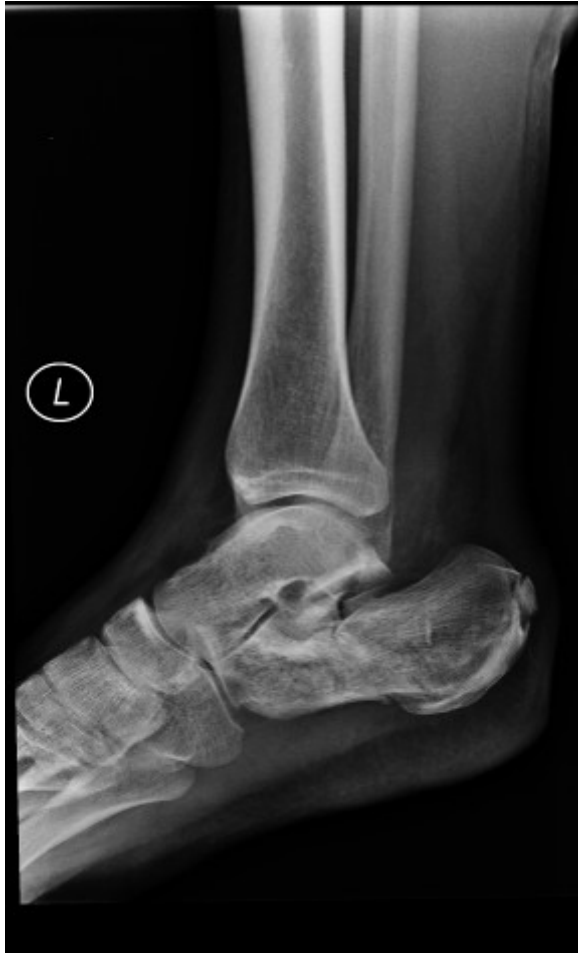ST3

Case 1

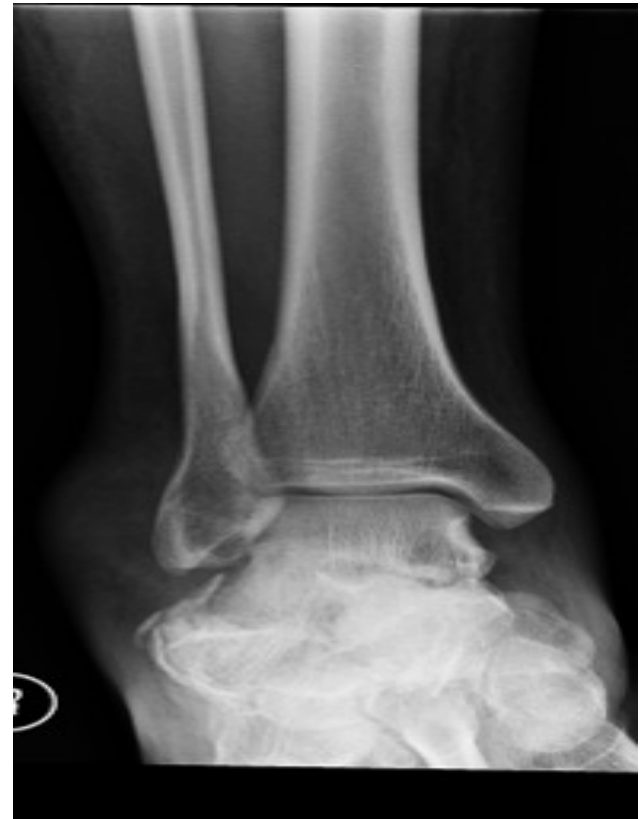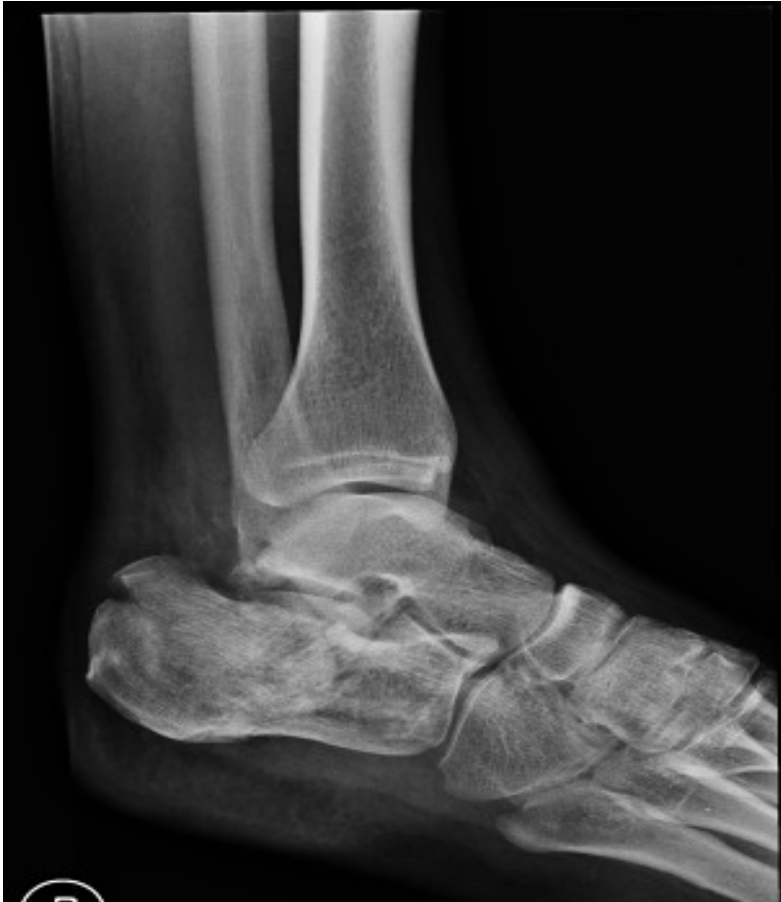Fall from tree



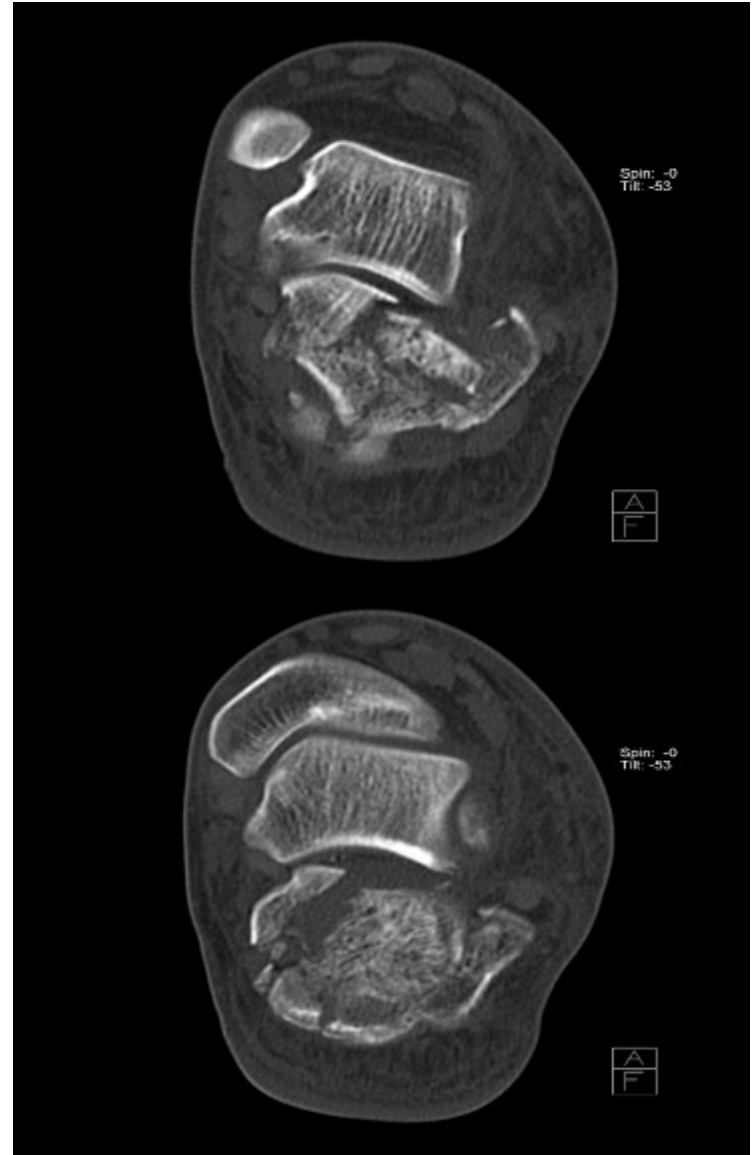
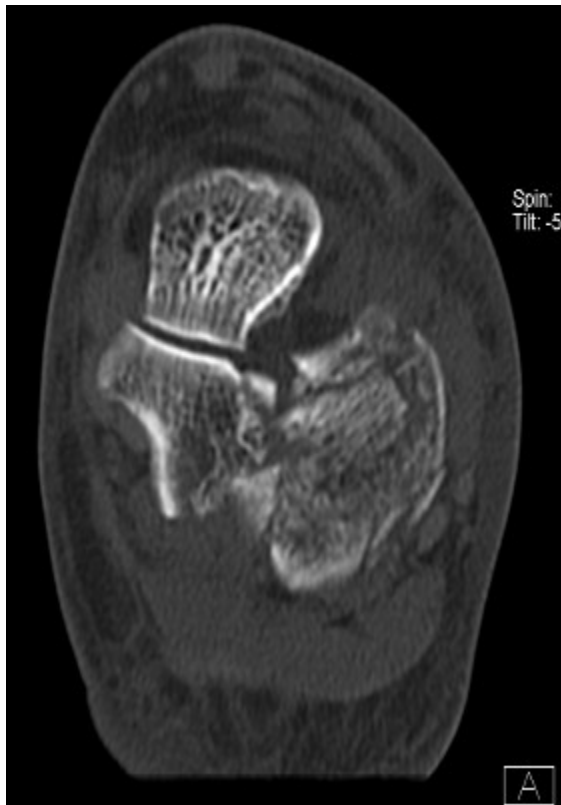Joint depression type



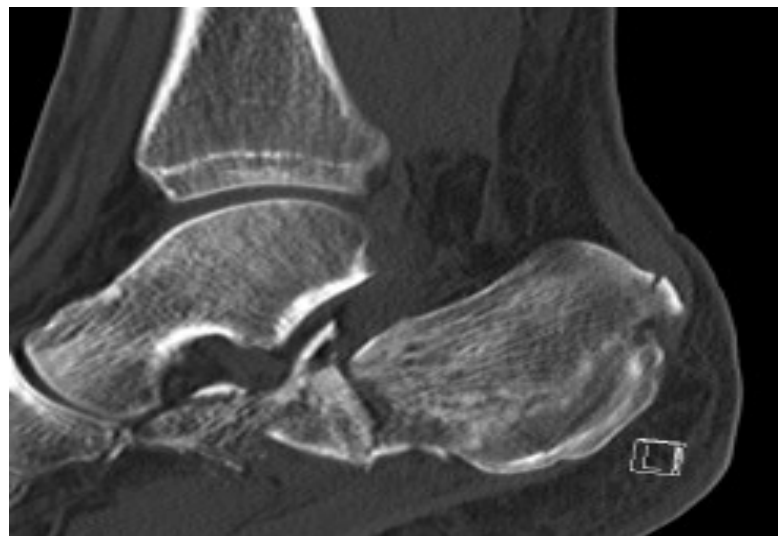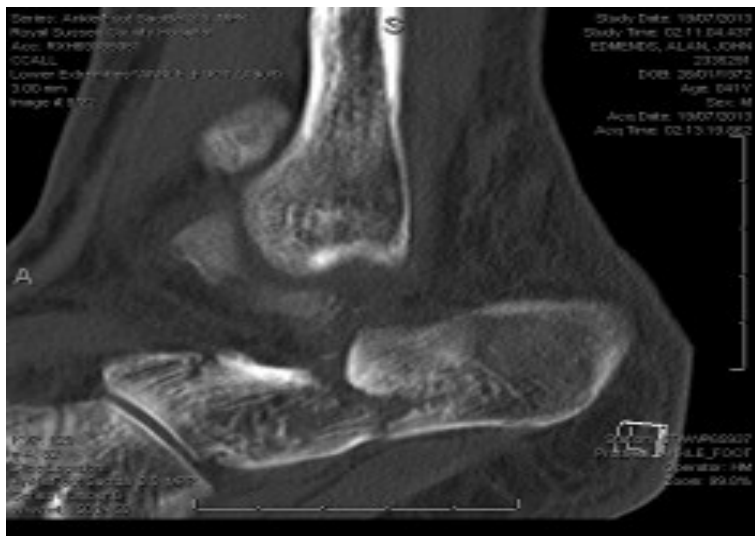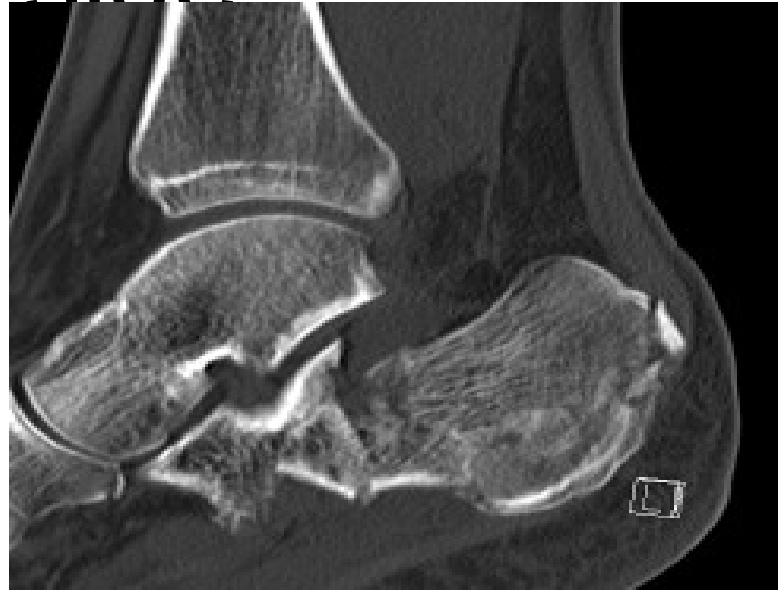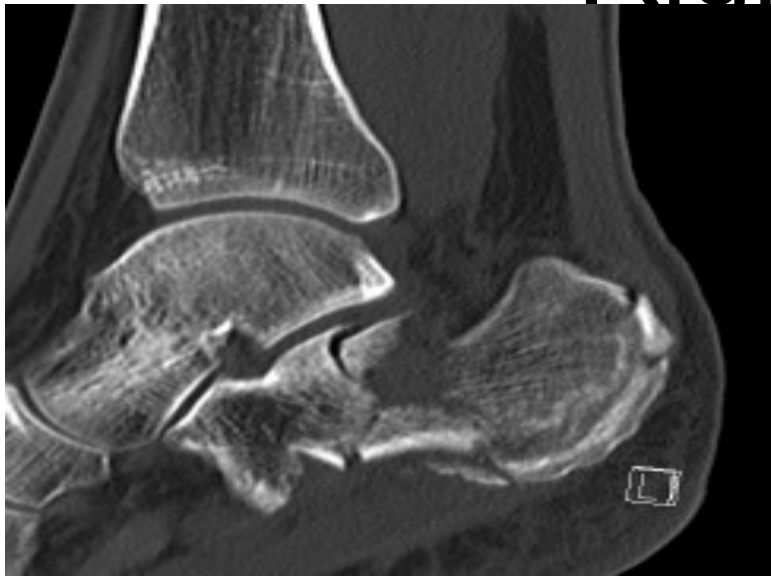Tongue type



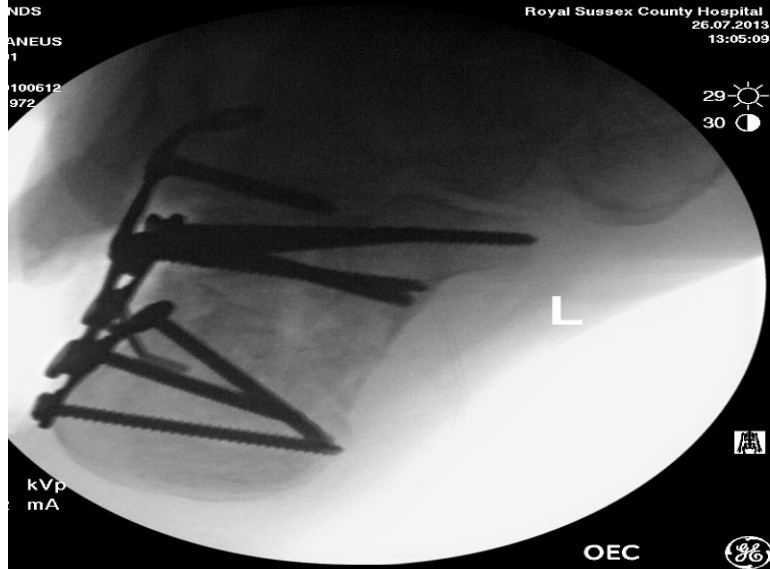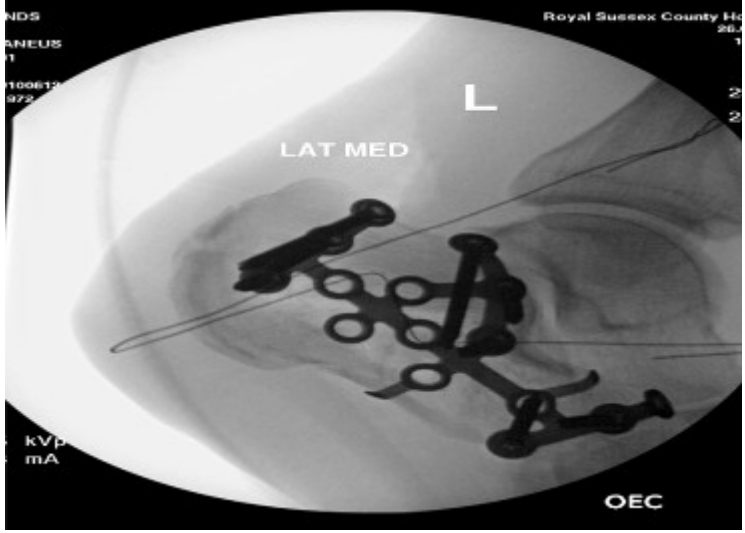
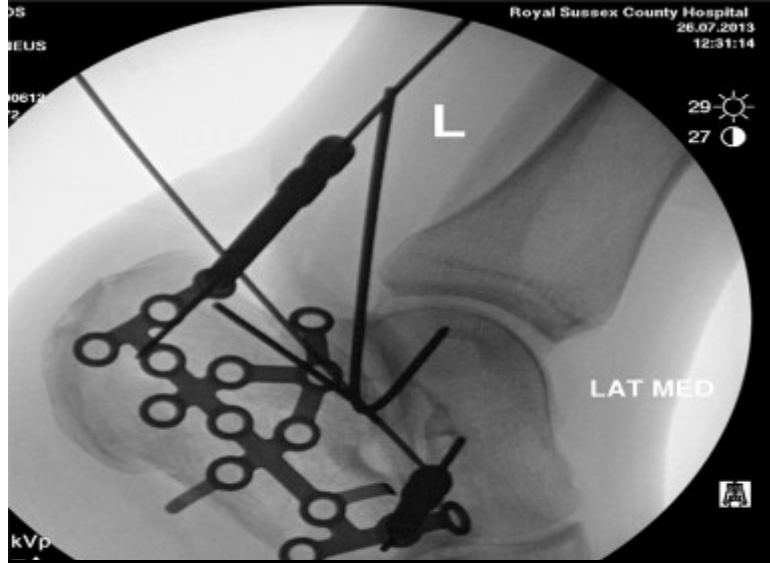
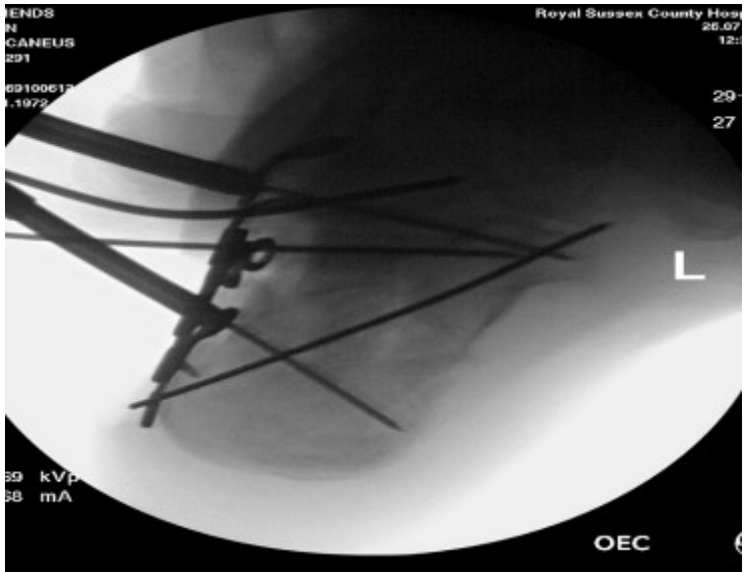
CT classification

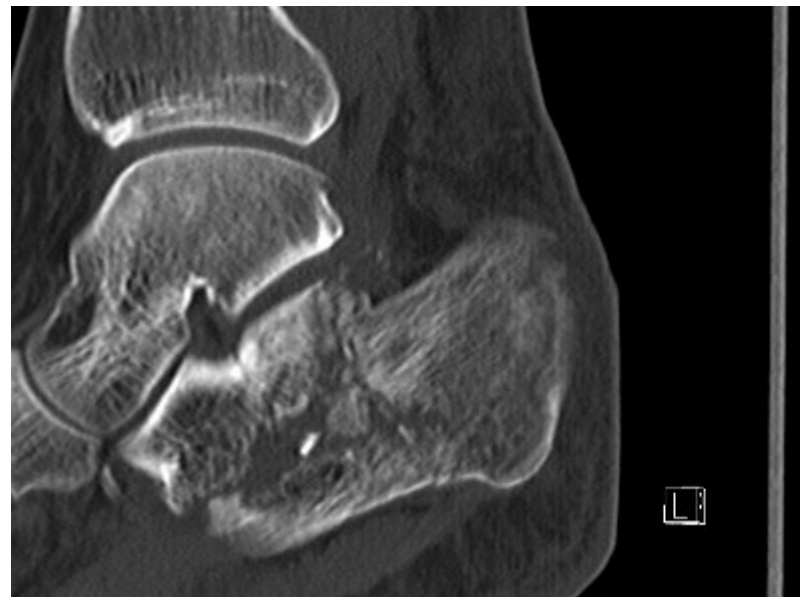
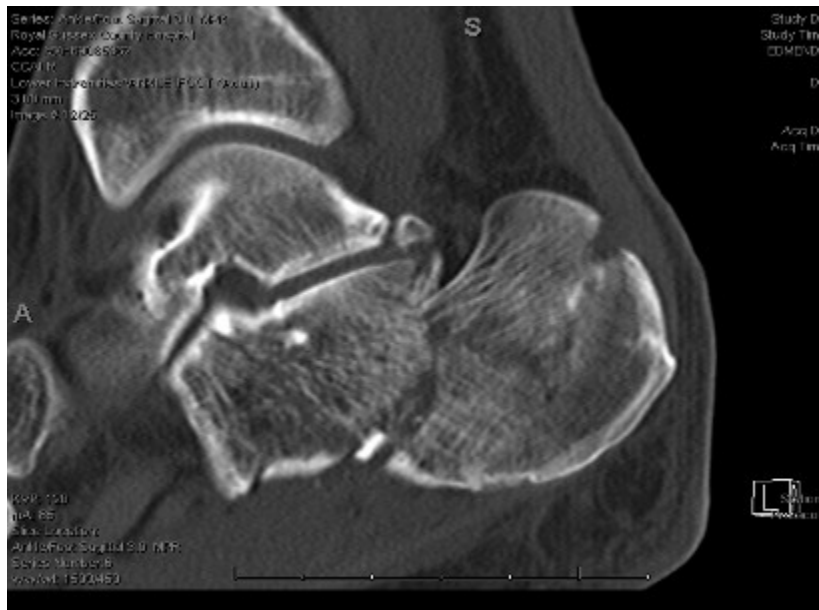
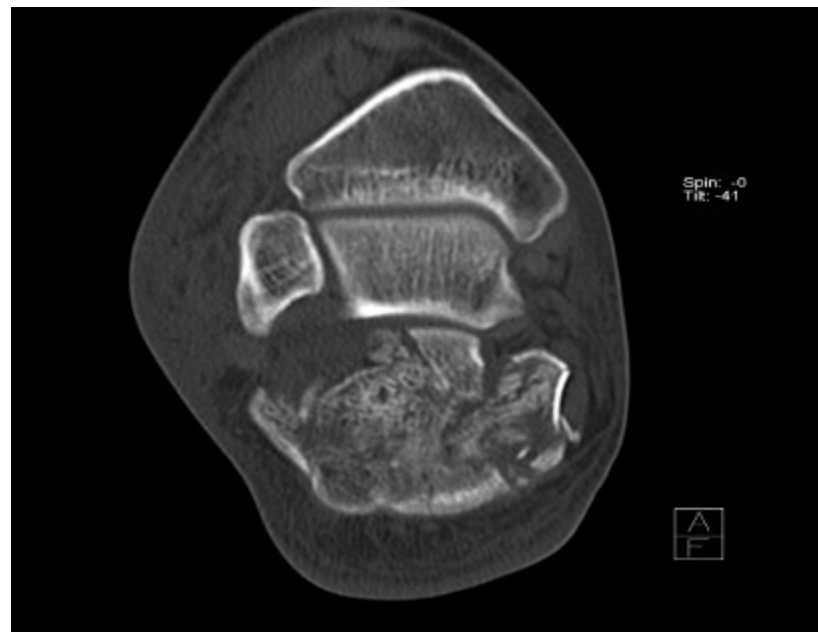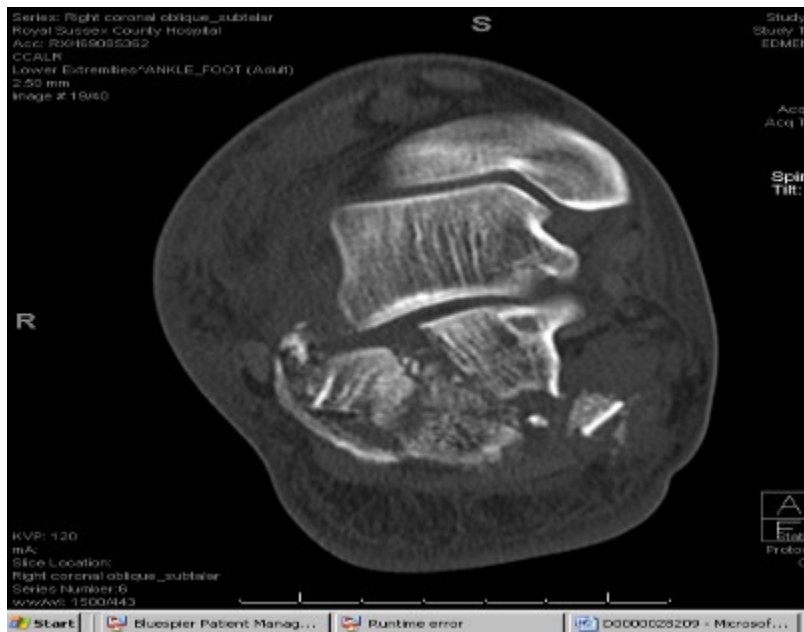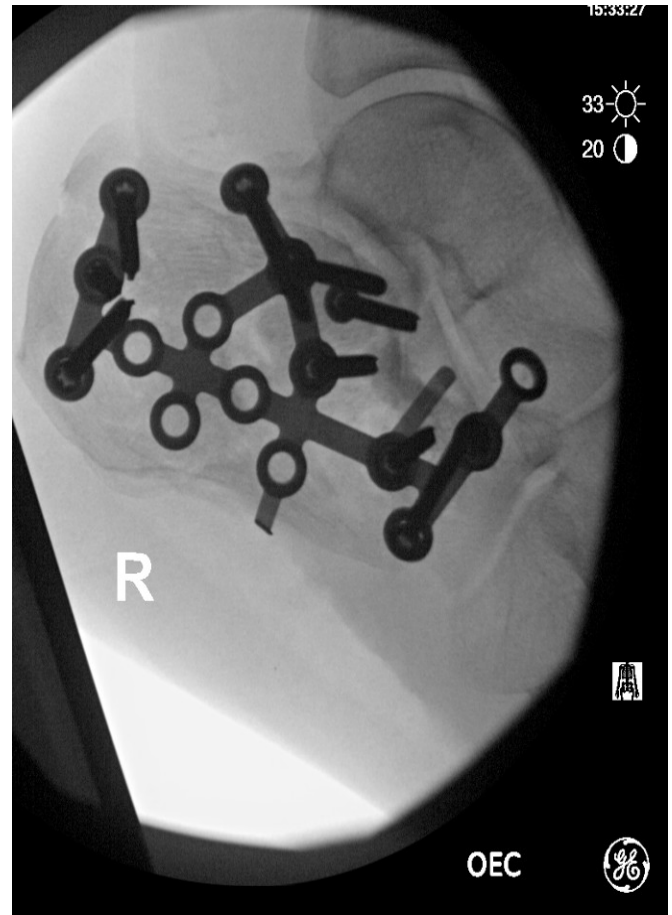
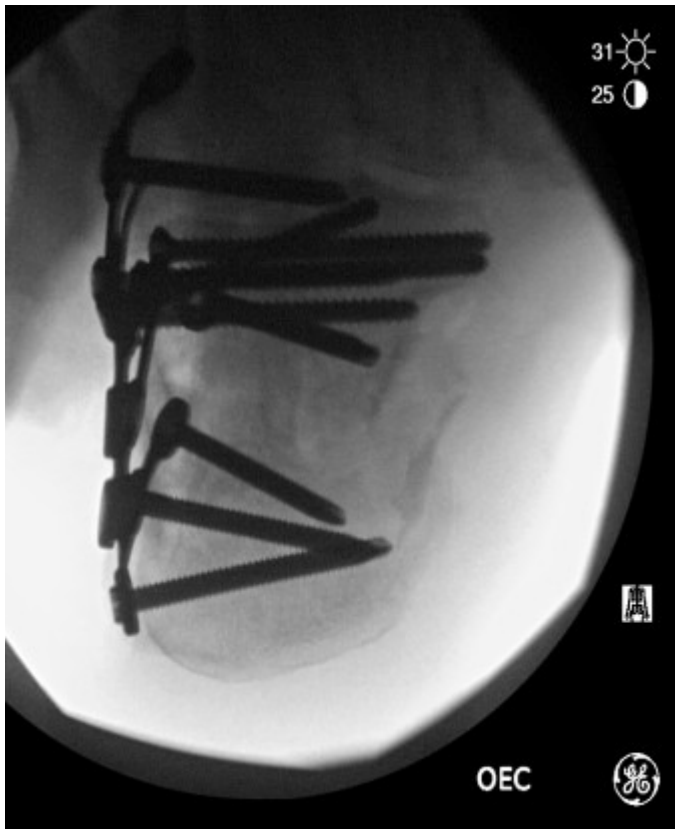Right side



Intra-op

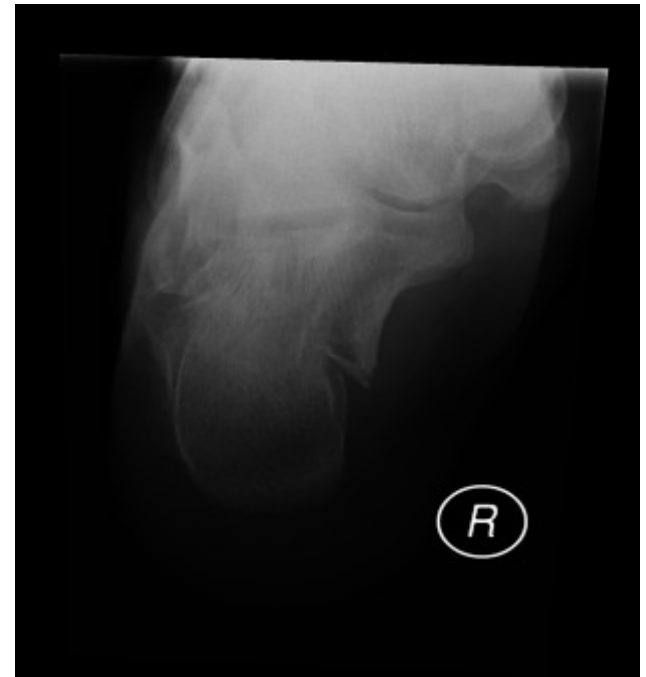
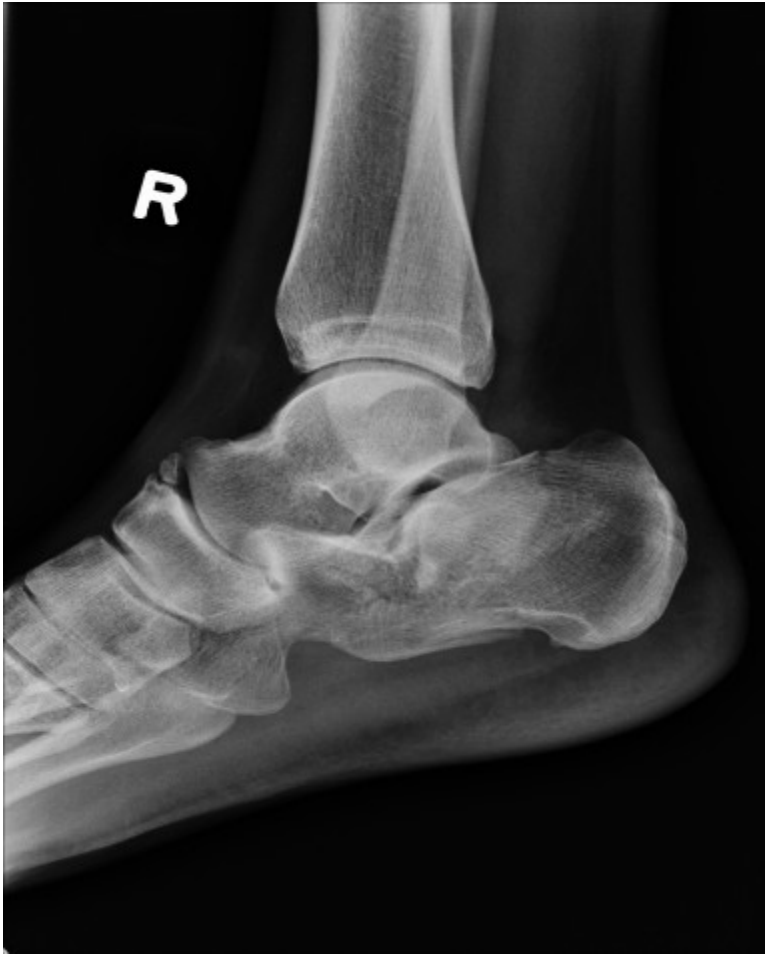




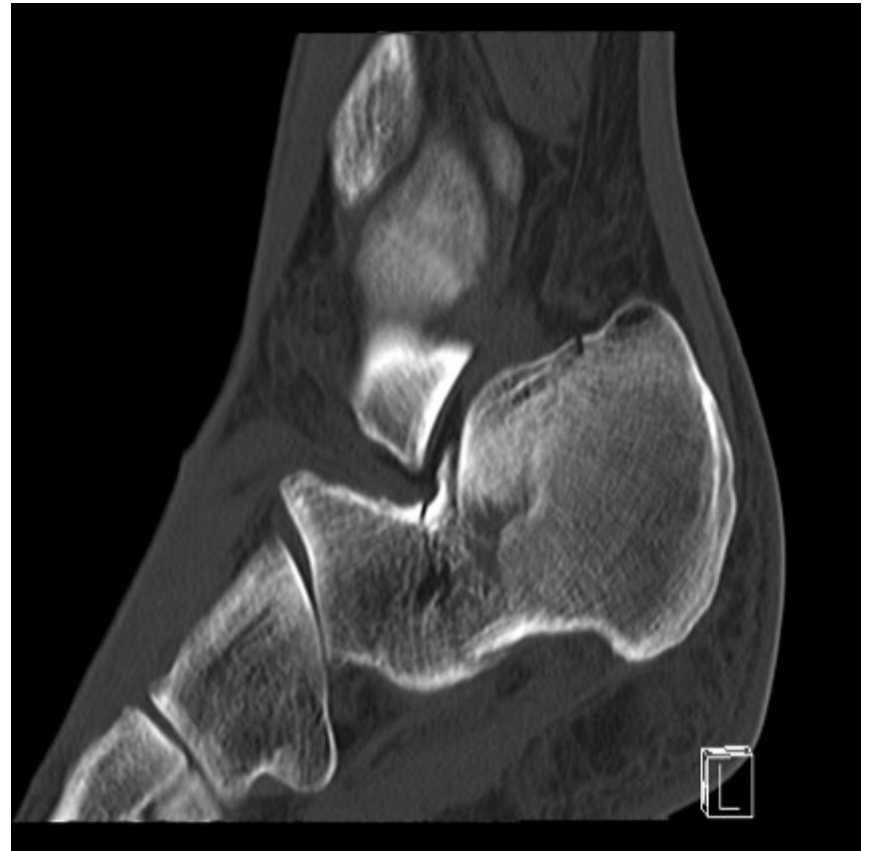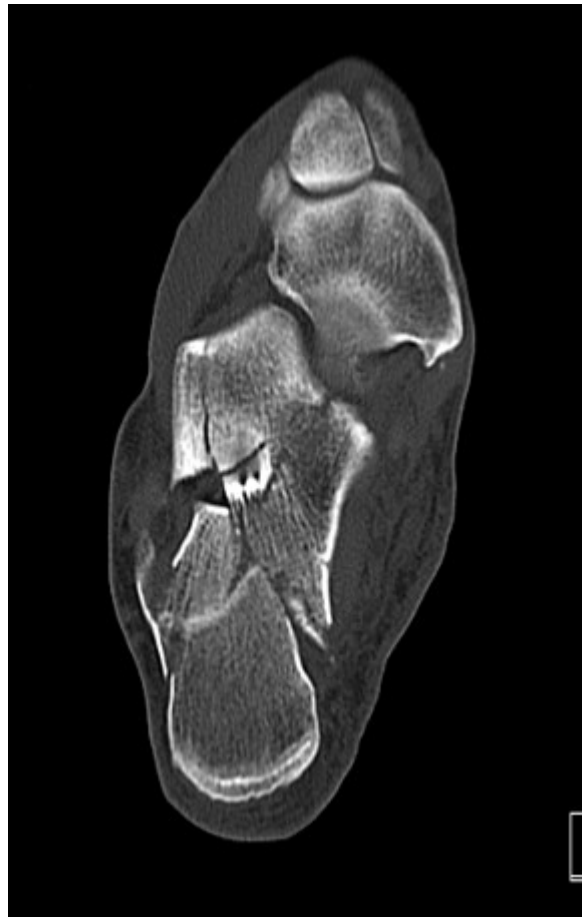Case 2

RTA

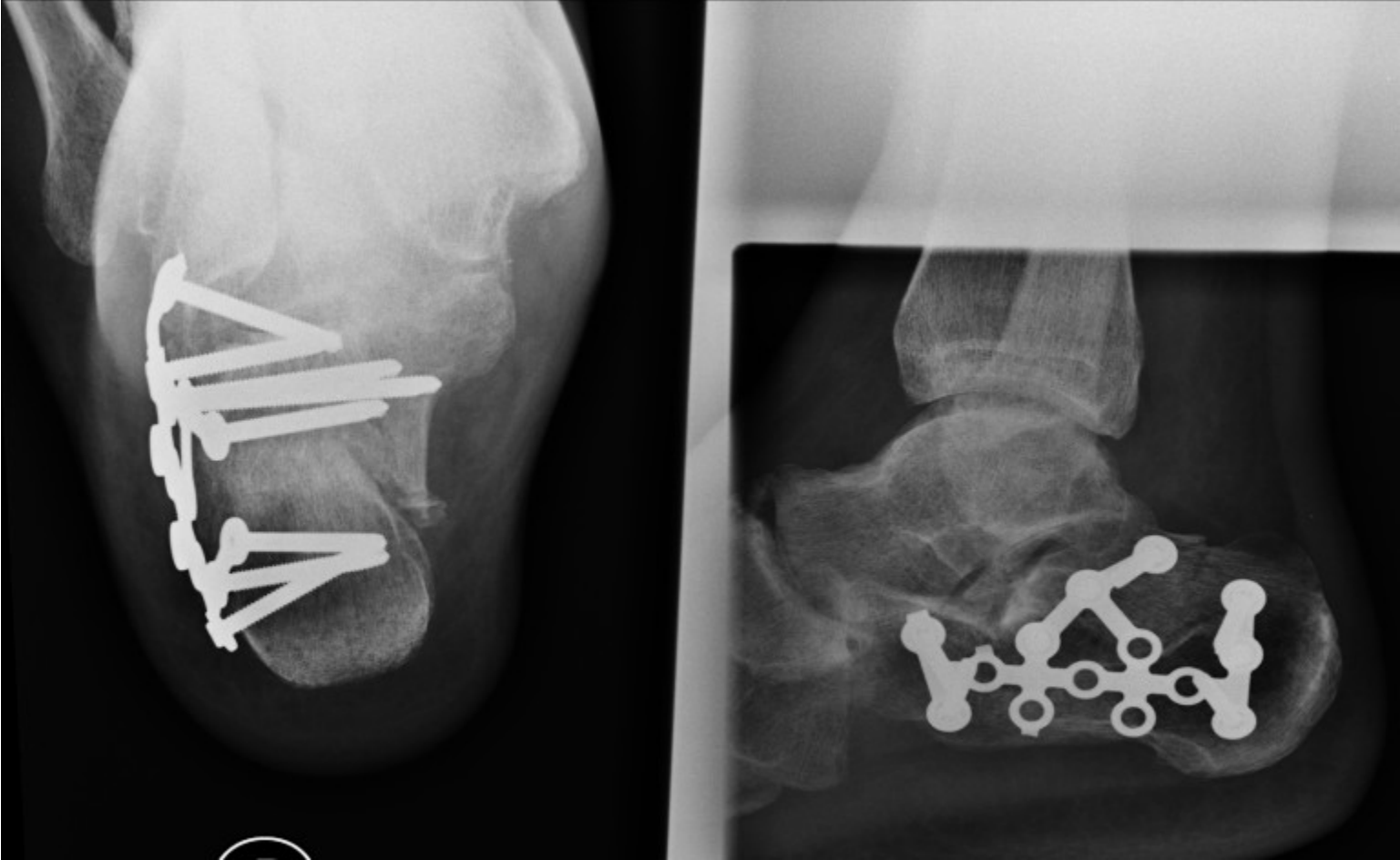


Case 2

Goals of surgery?

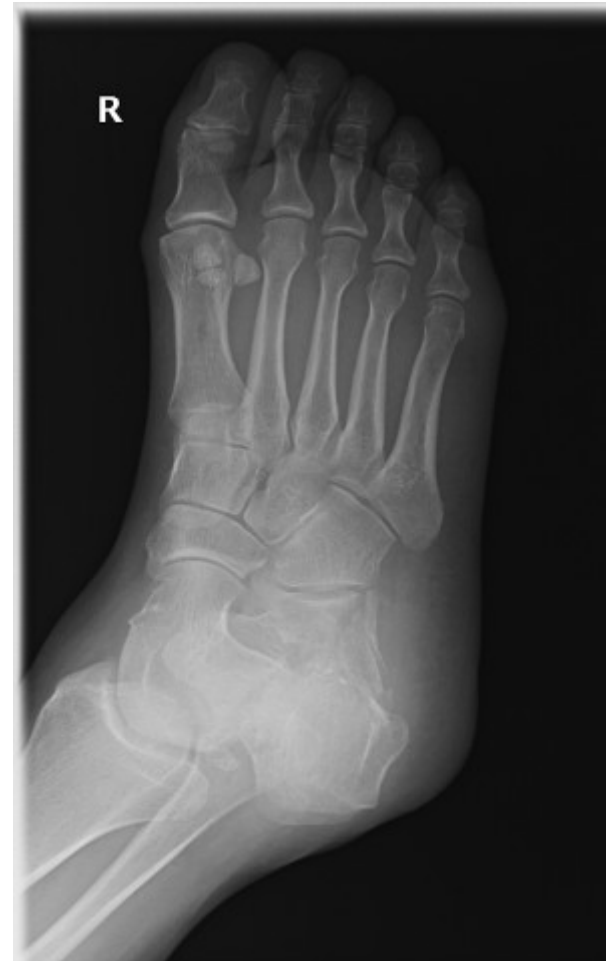
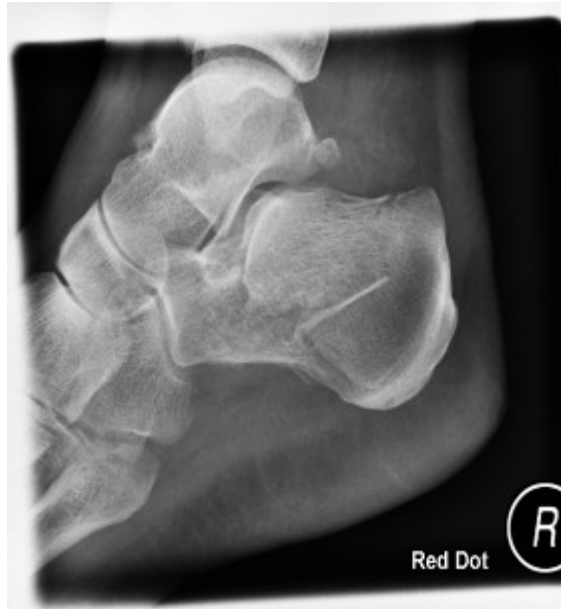
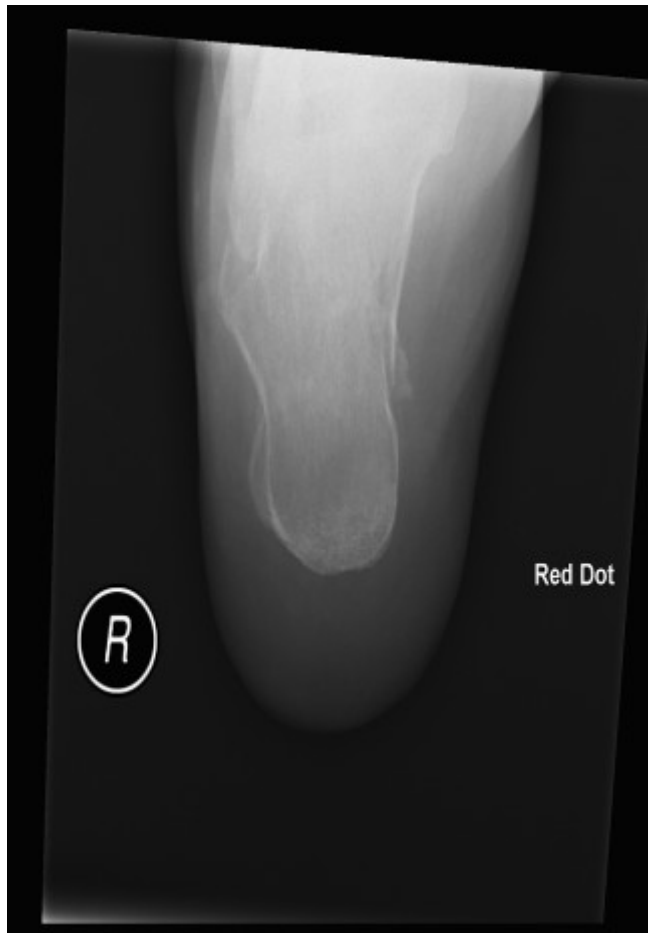?

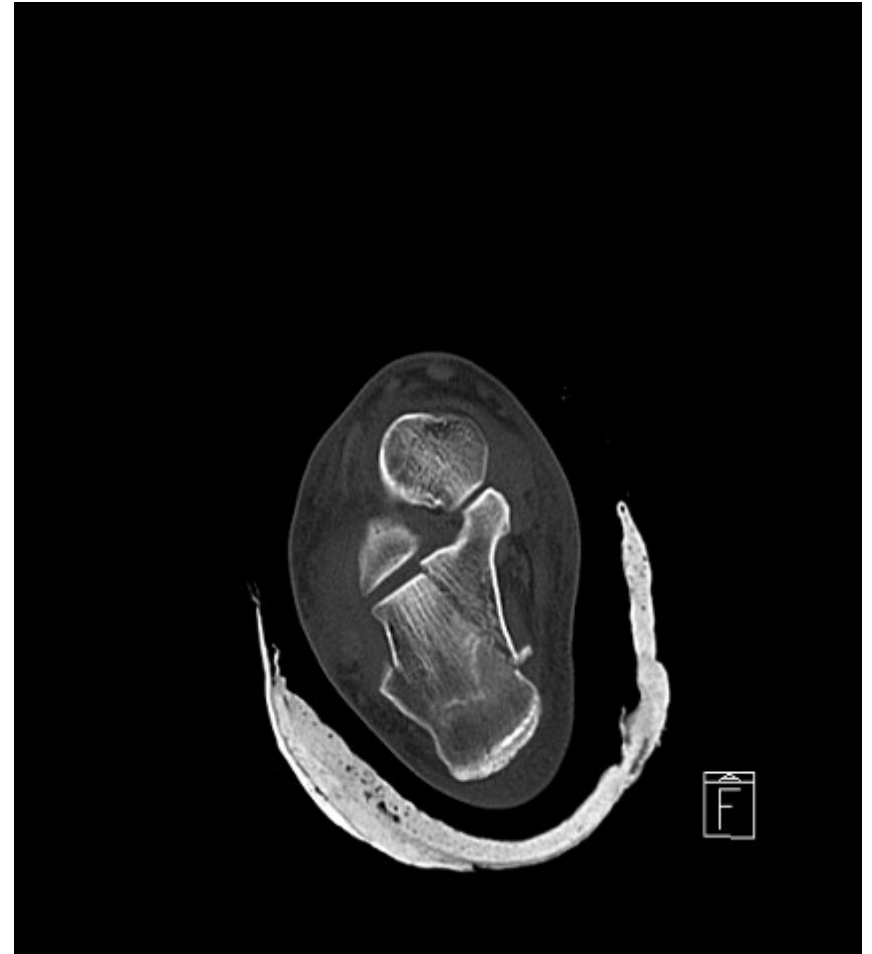
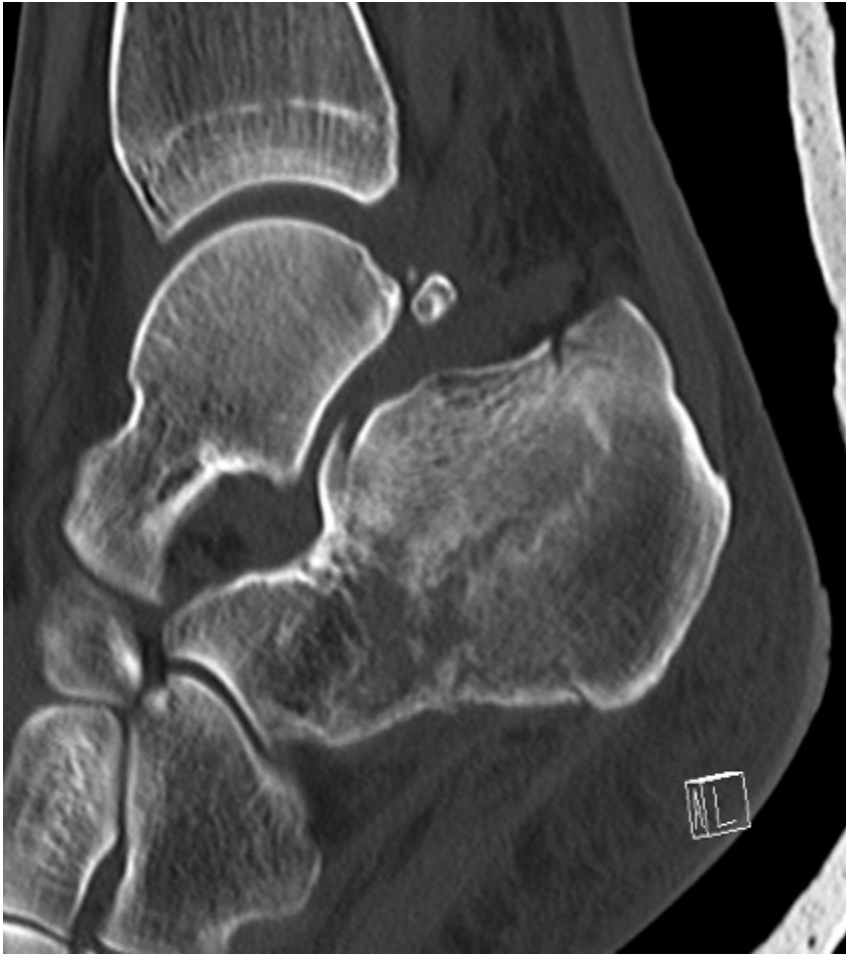
Case 3

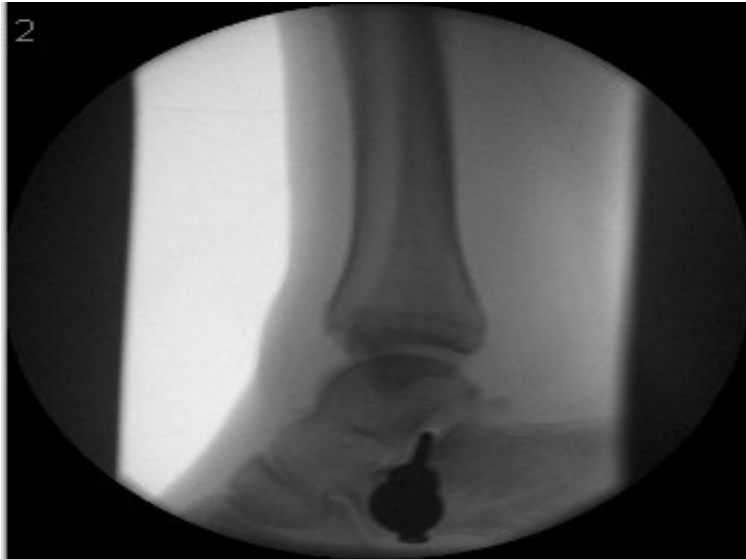Young diabetic



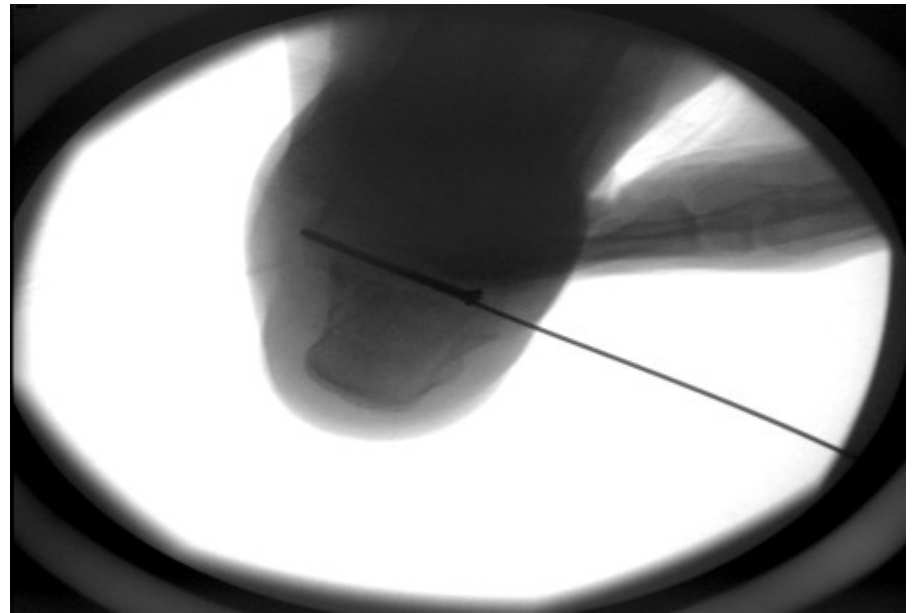
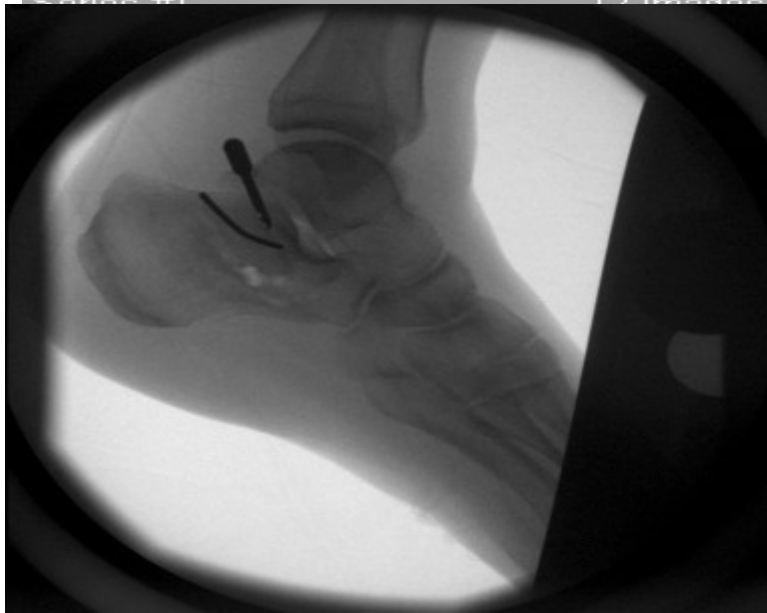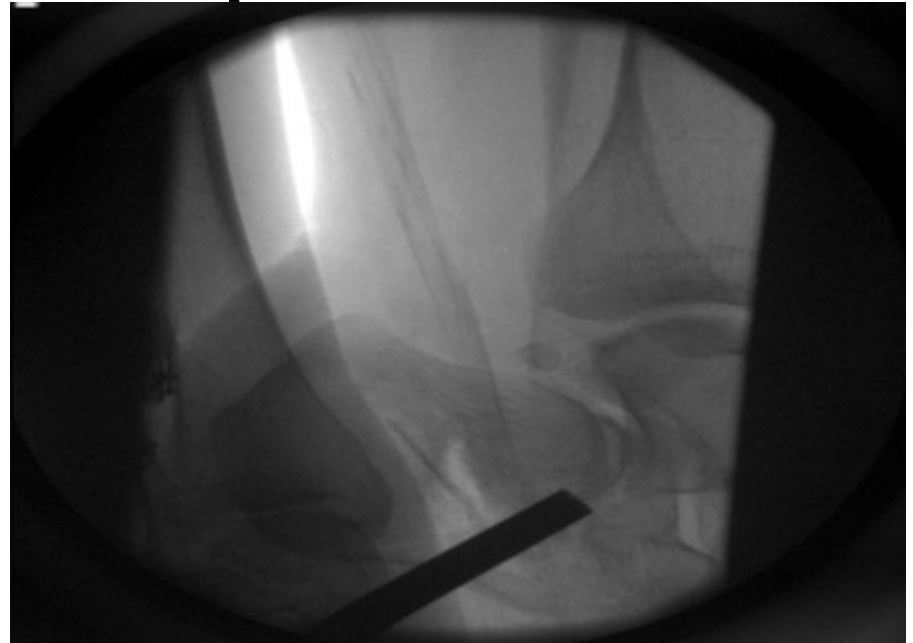
Sander ?



MIS in selected patients



Orthopaedic Pinning Lower Lw/I: 3350/1889
Series #1 12 Images



6 months post op

