

Challenging cases treated by Ilizarov

Fahed Yousief Alserhan M.D

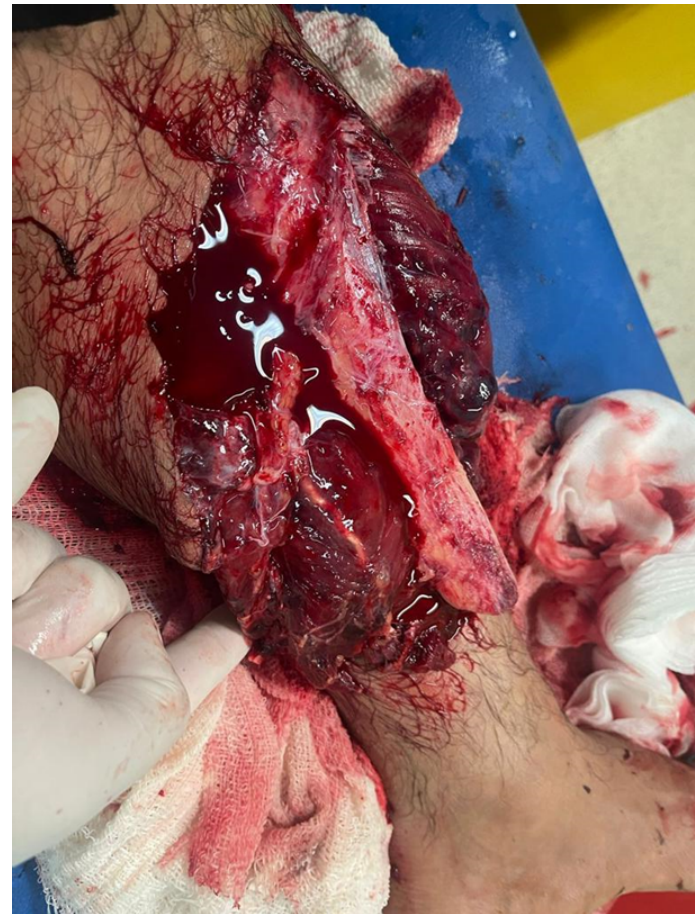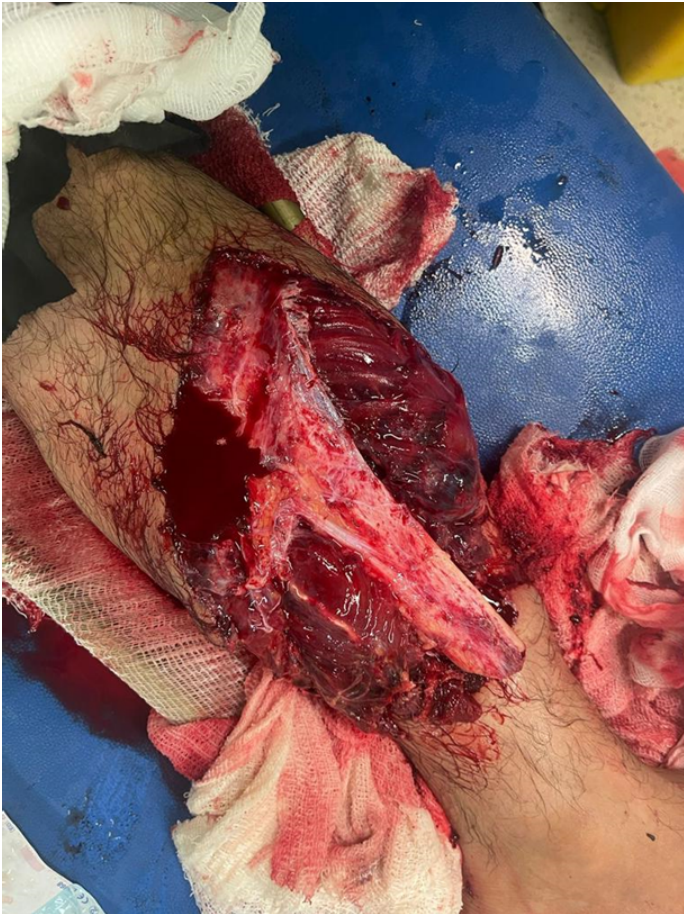Advance Trauma & Orthopedic
LRS And Deformity Correction

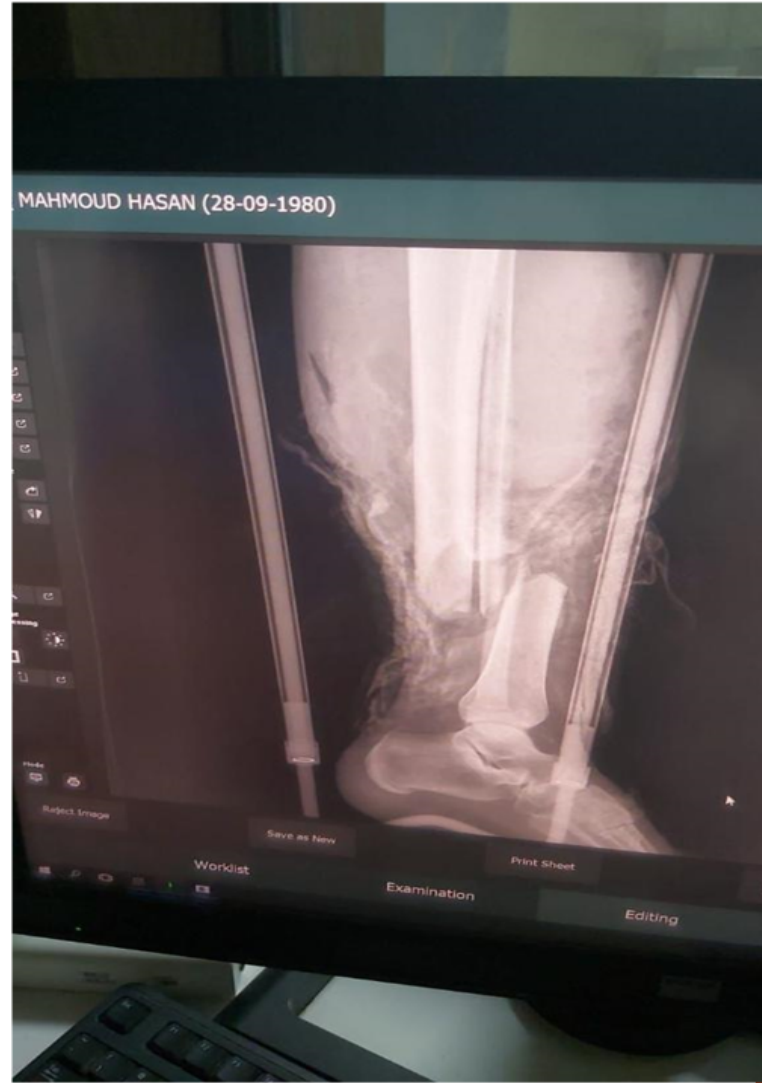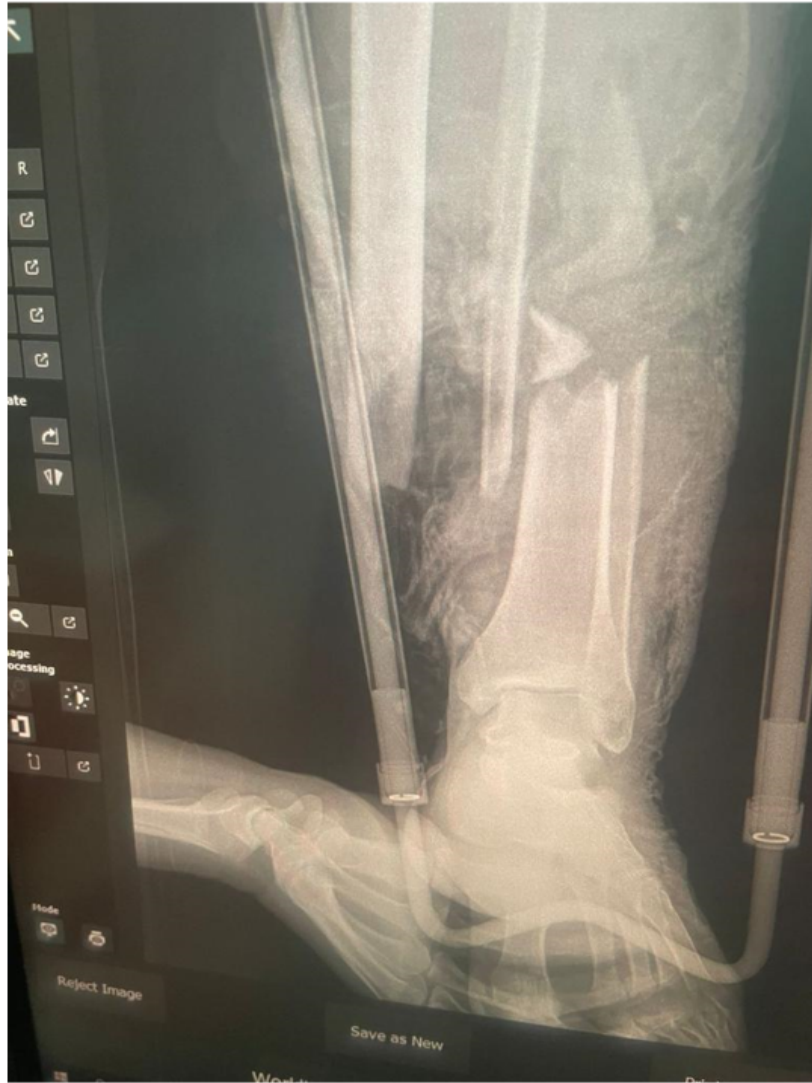Case 1

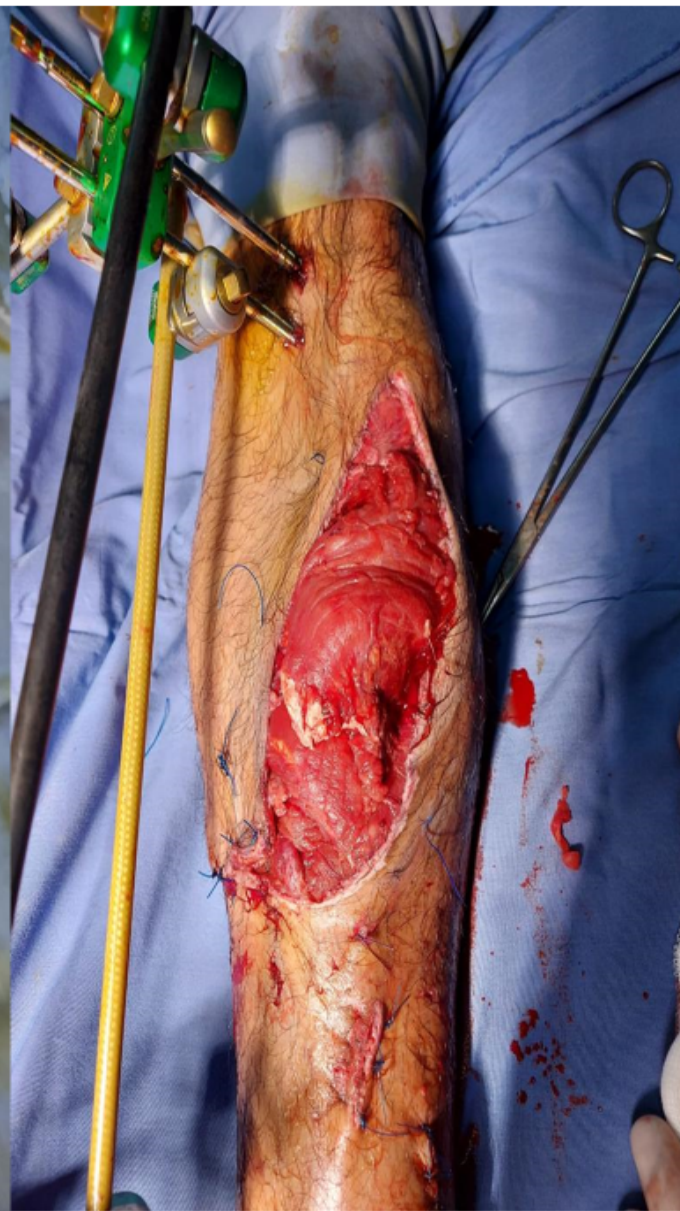
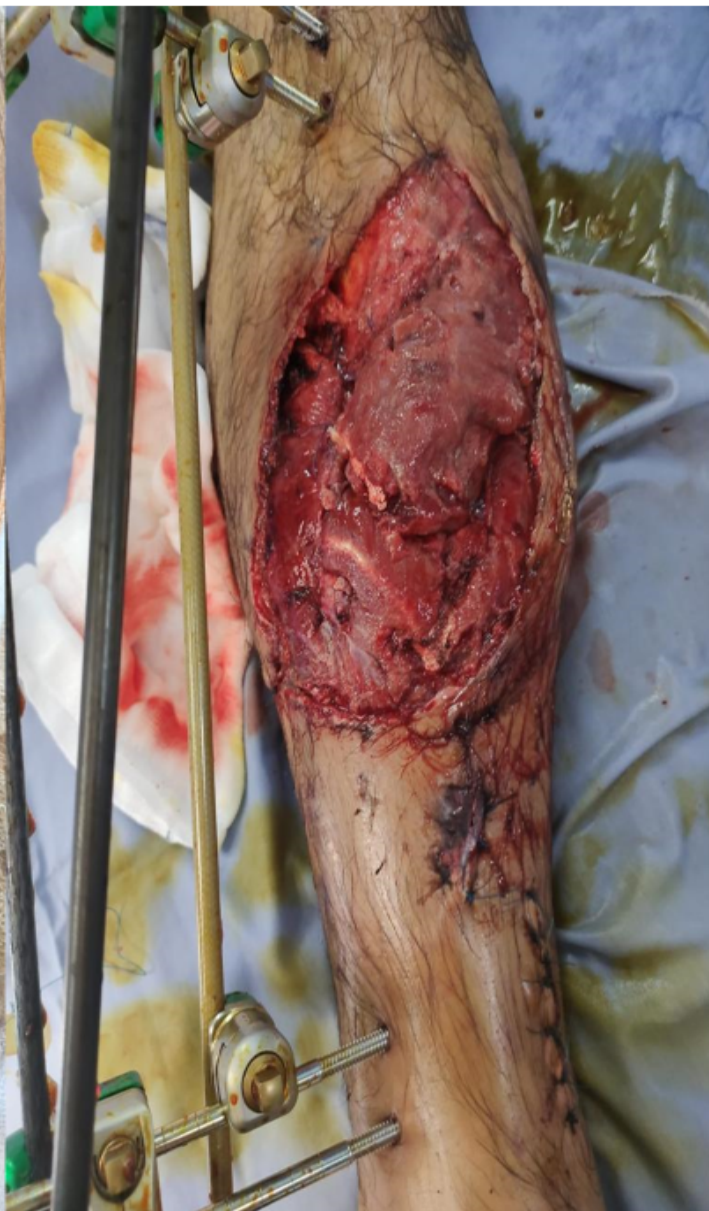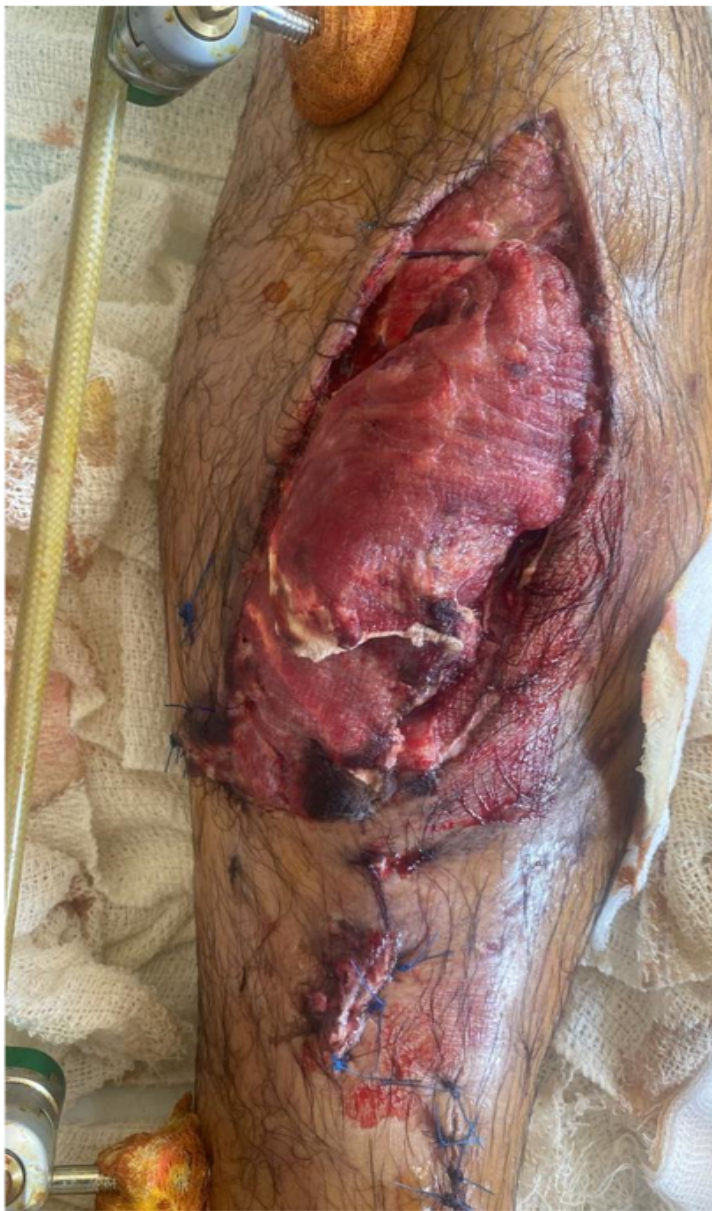38 years, male

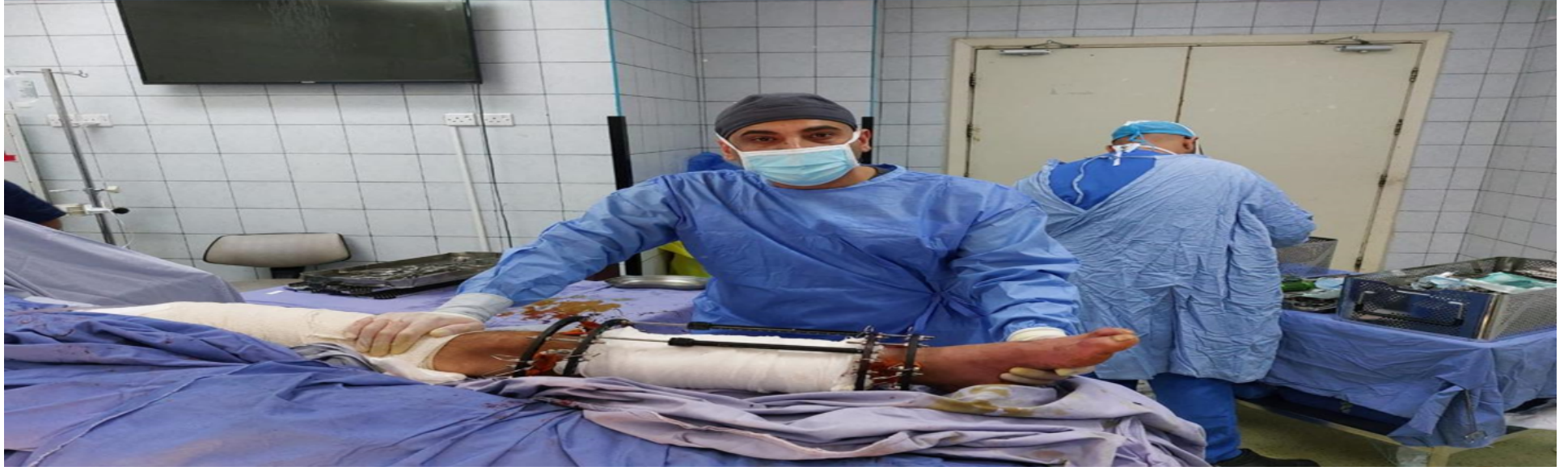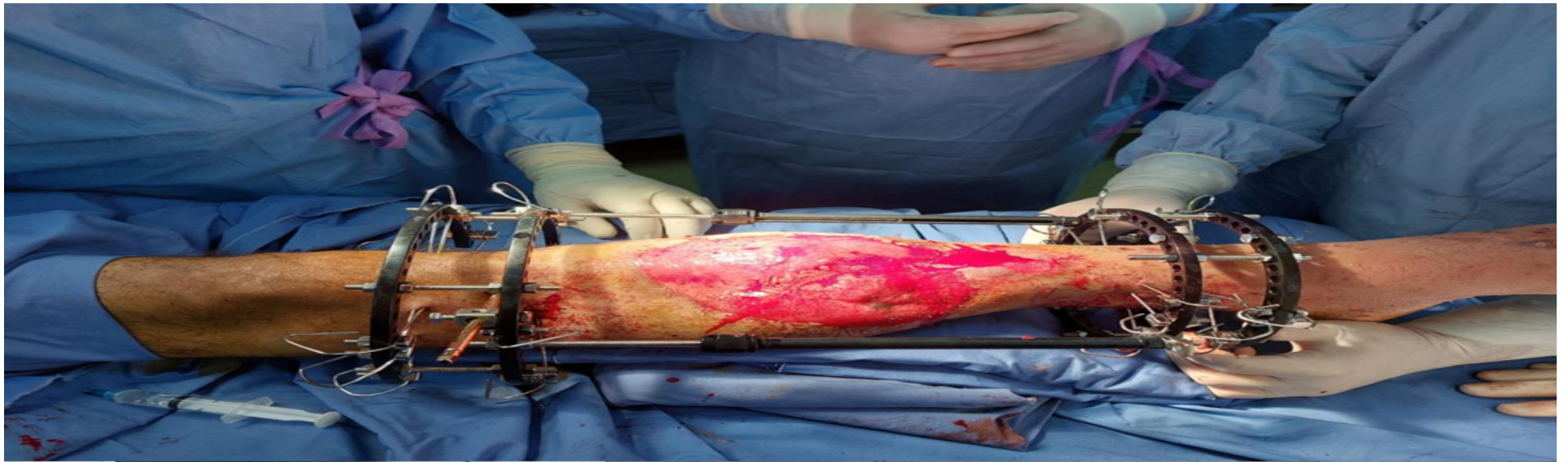RTA, roll-over

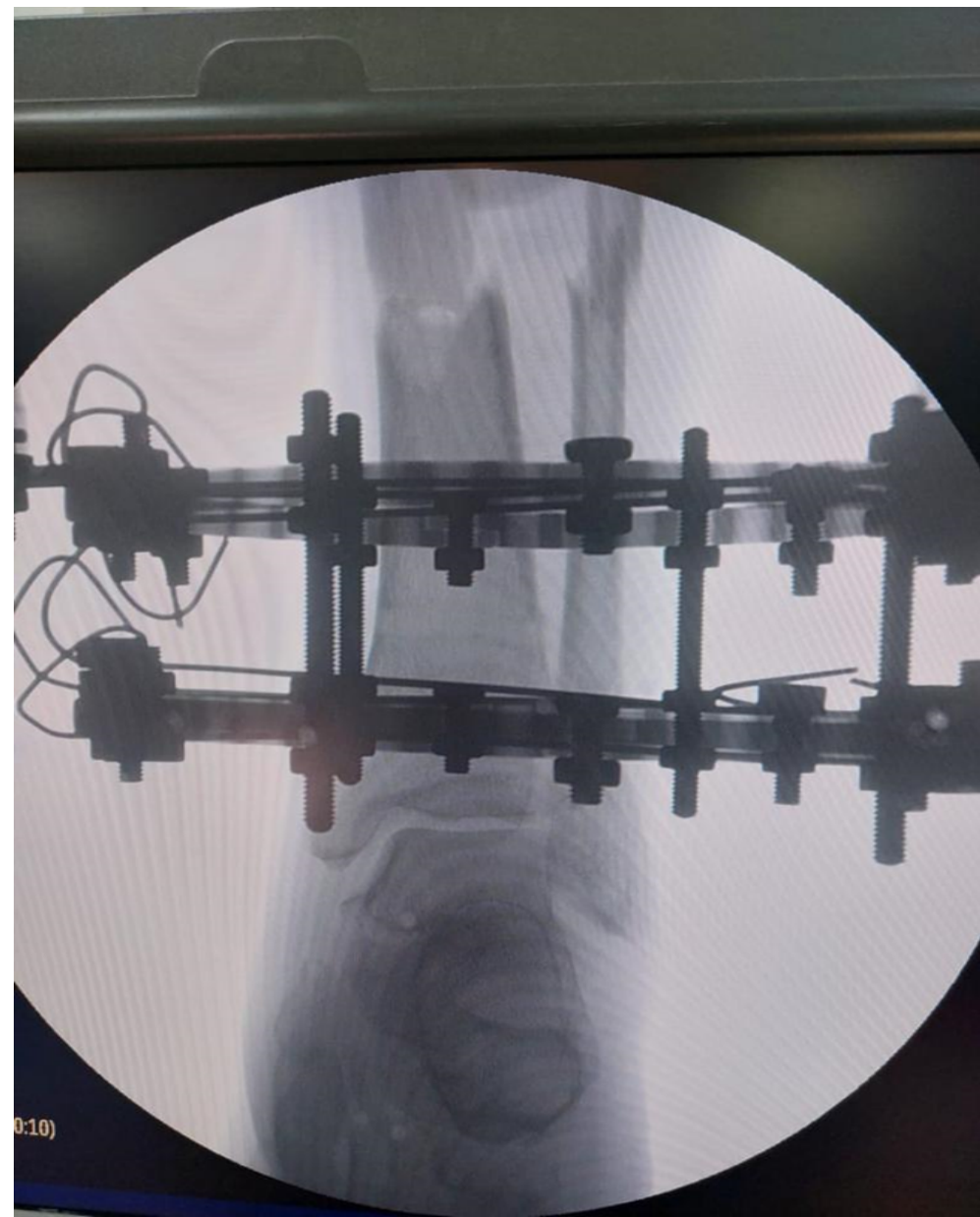
Open tibia with vascular insult

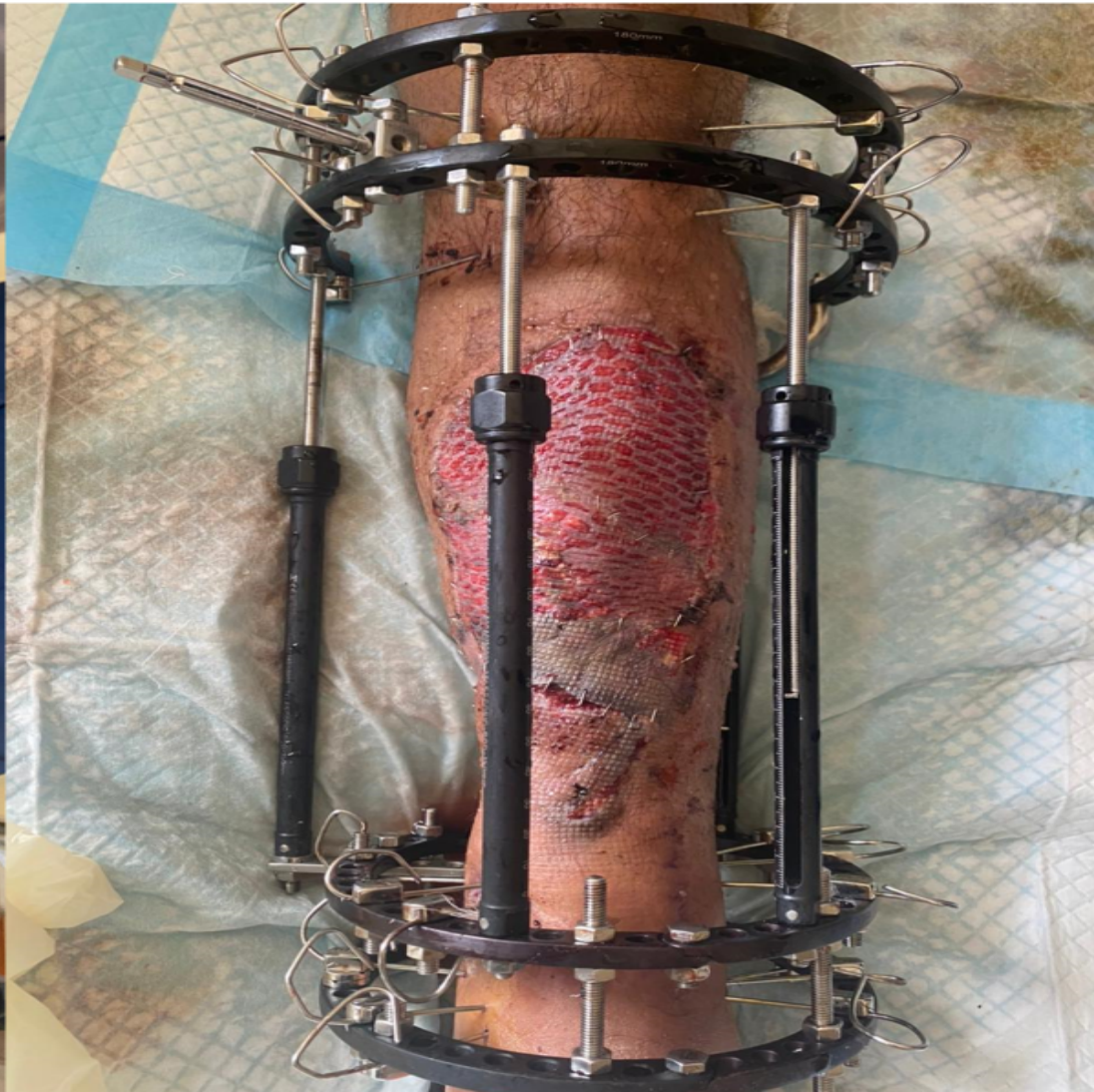
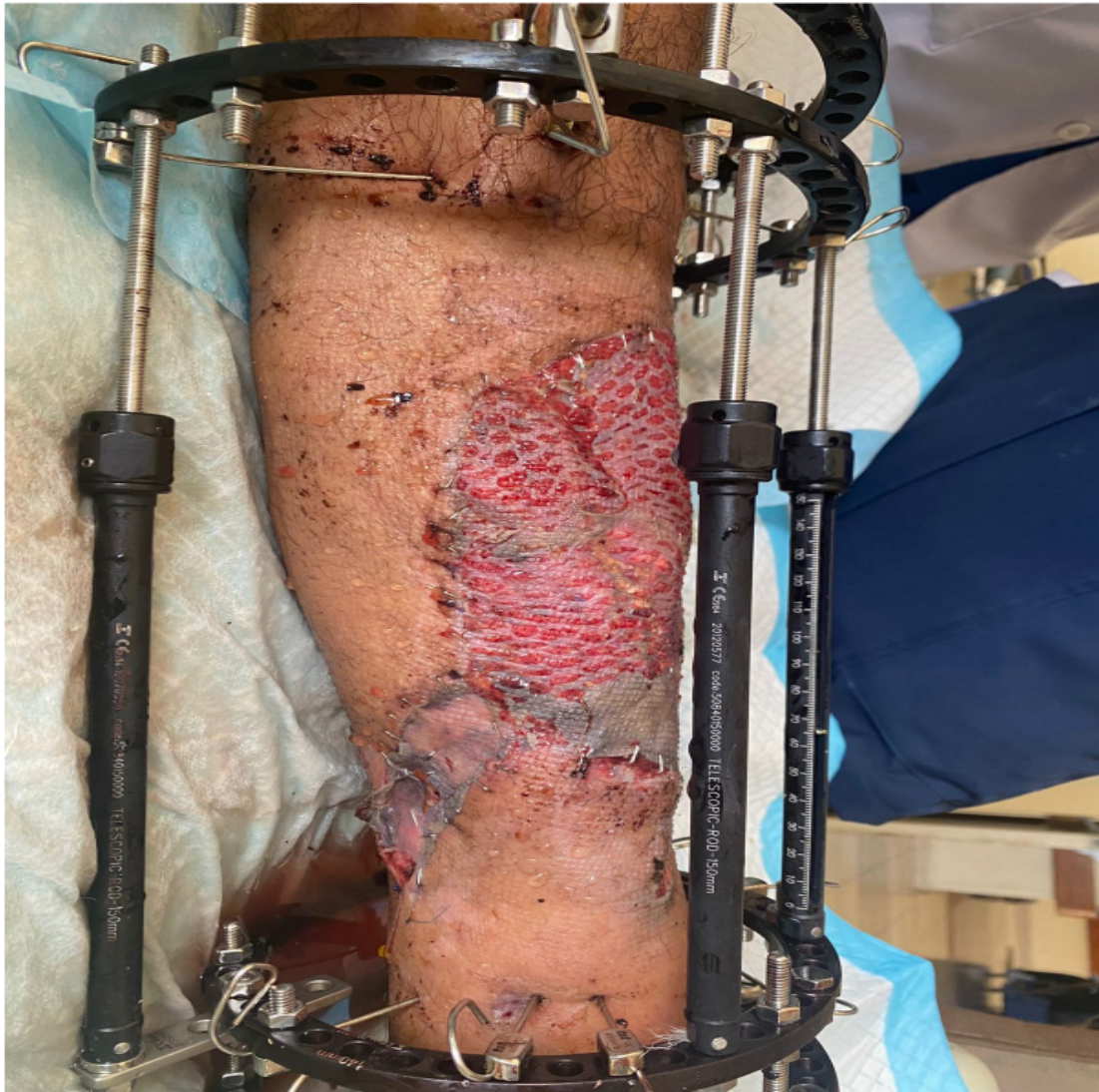


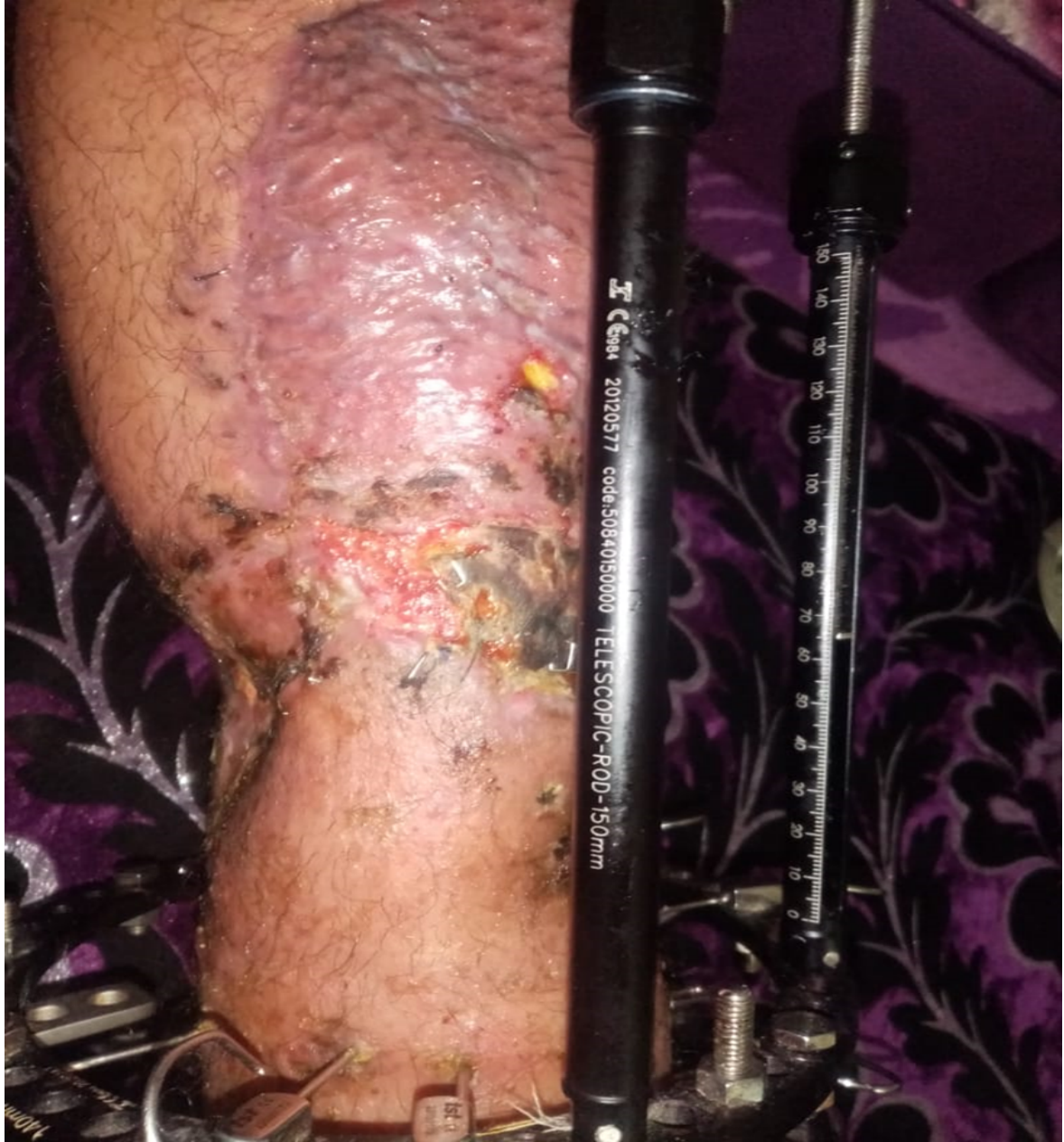



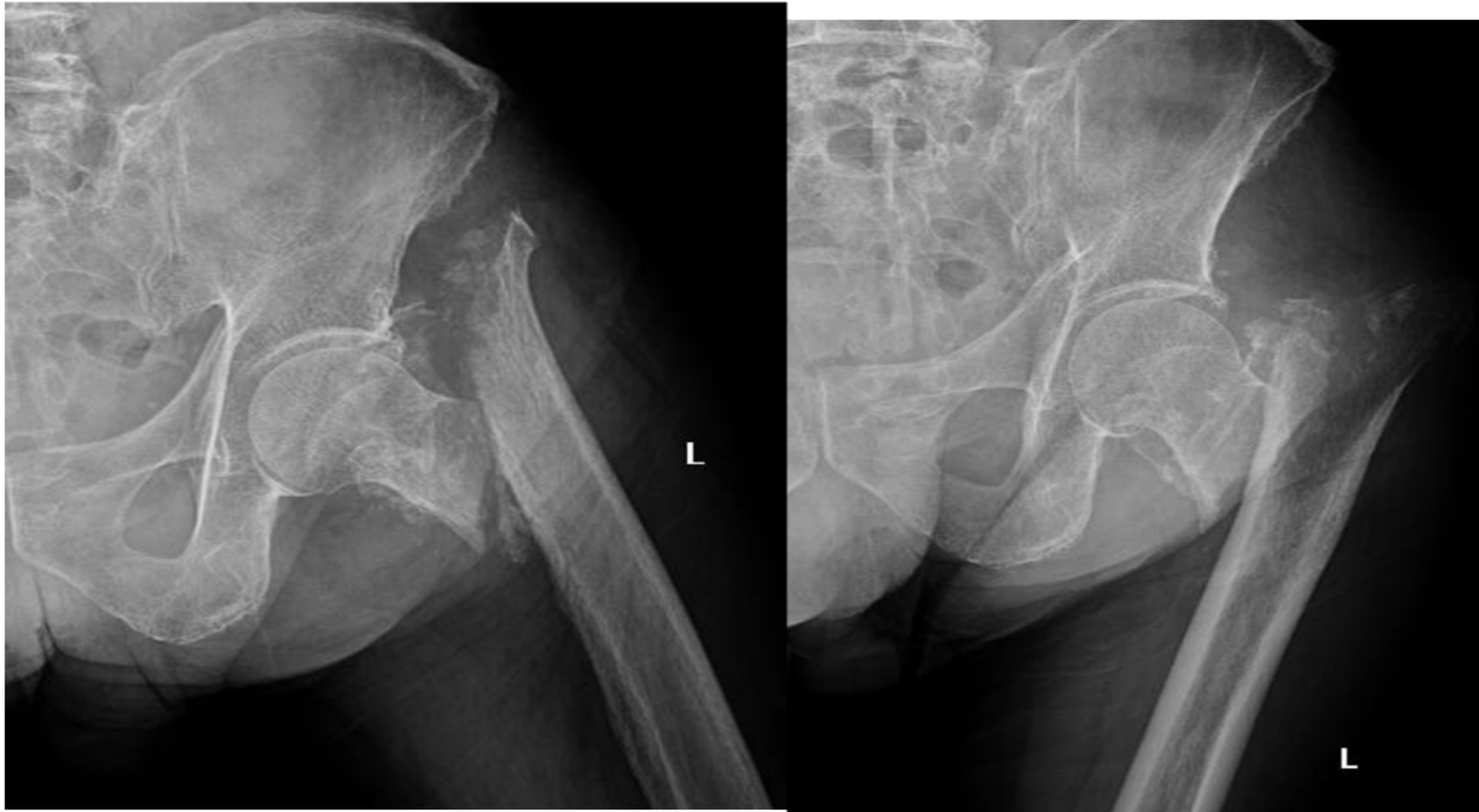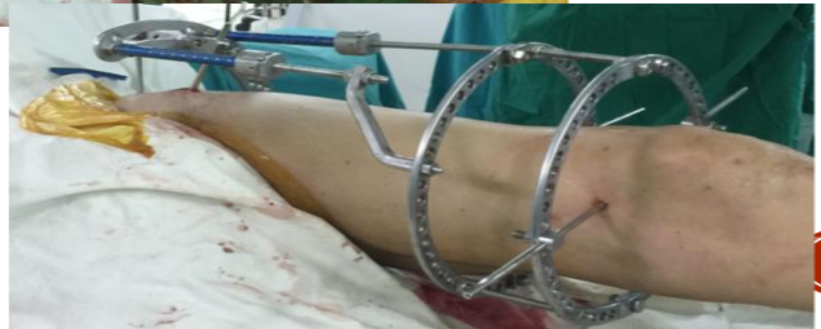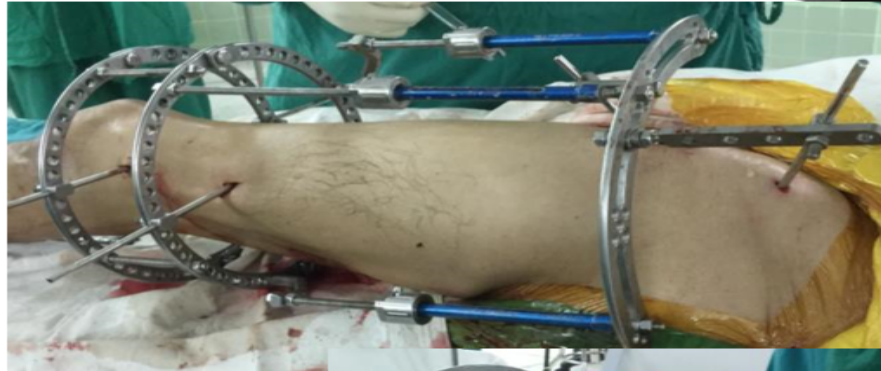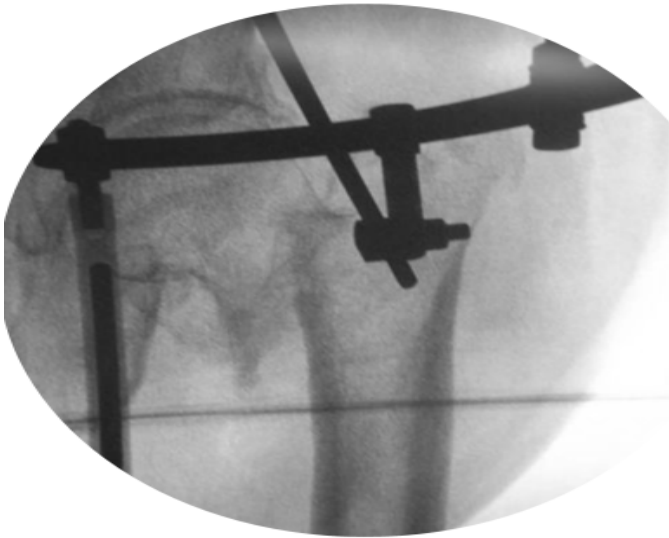
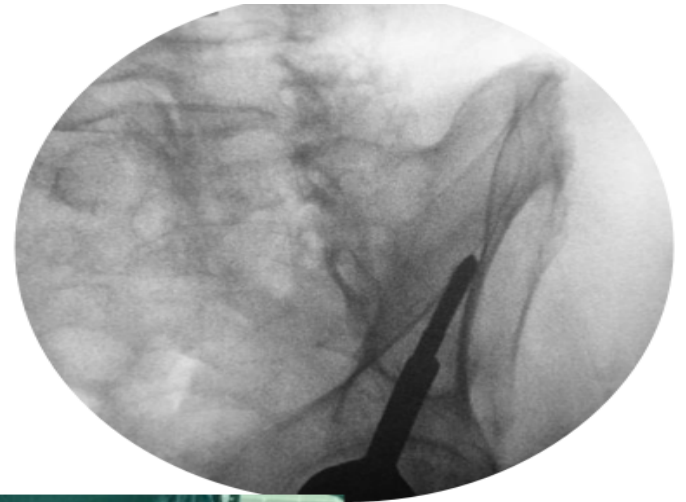
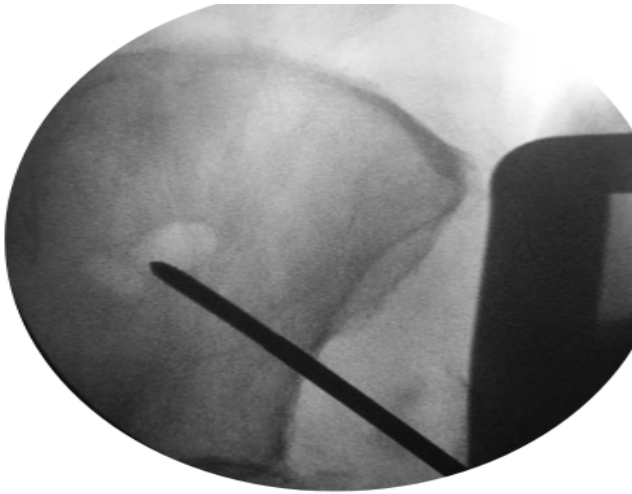






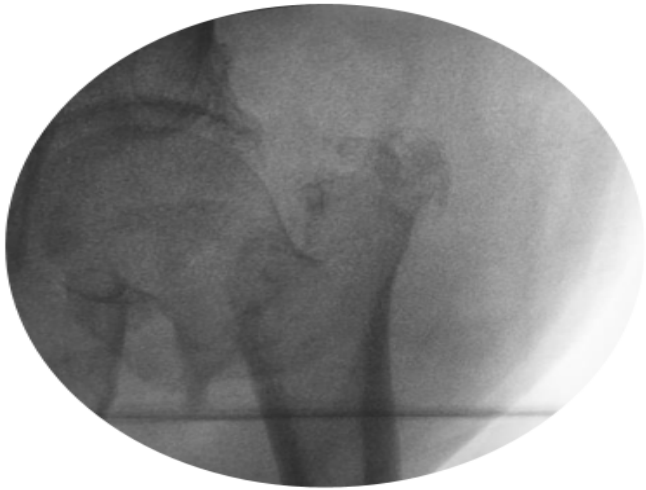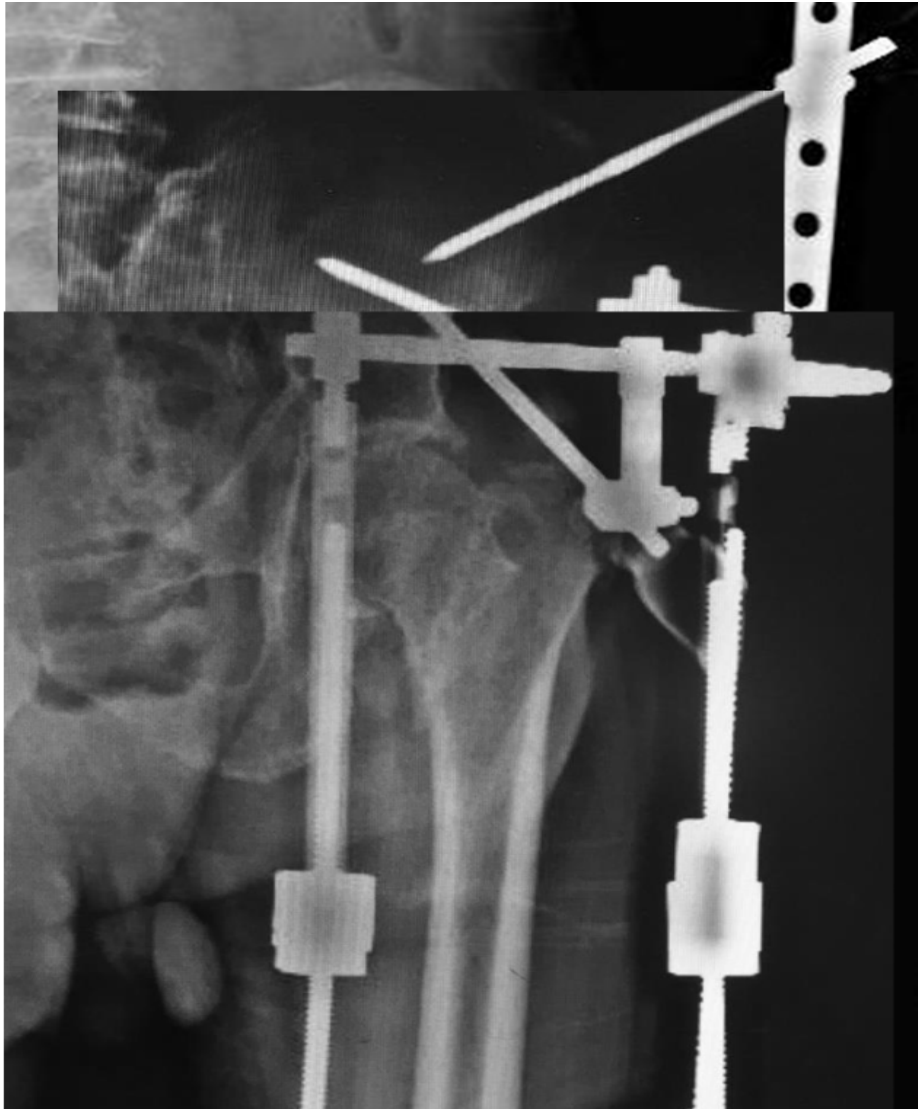**73 years old male : Neglected fracture for 4 months
How to mobilize the fracture and fix without surgical release ?**



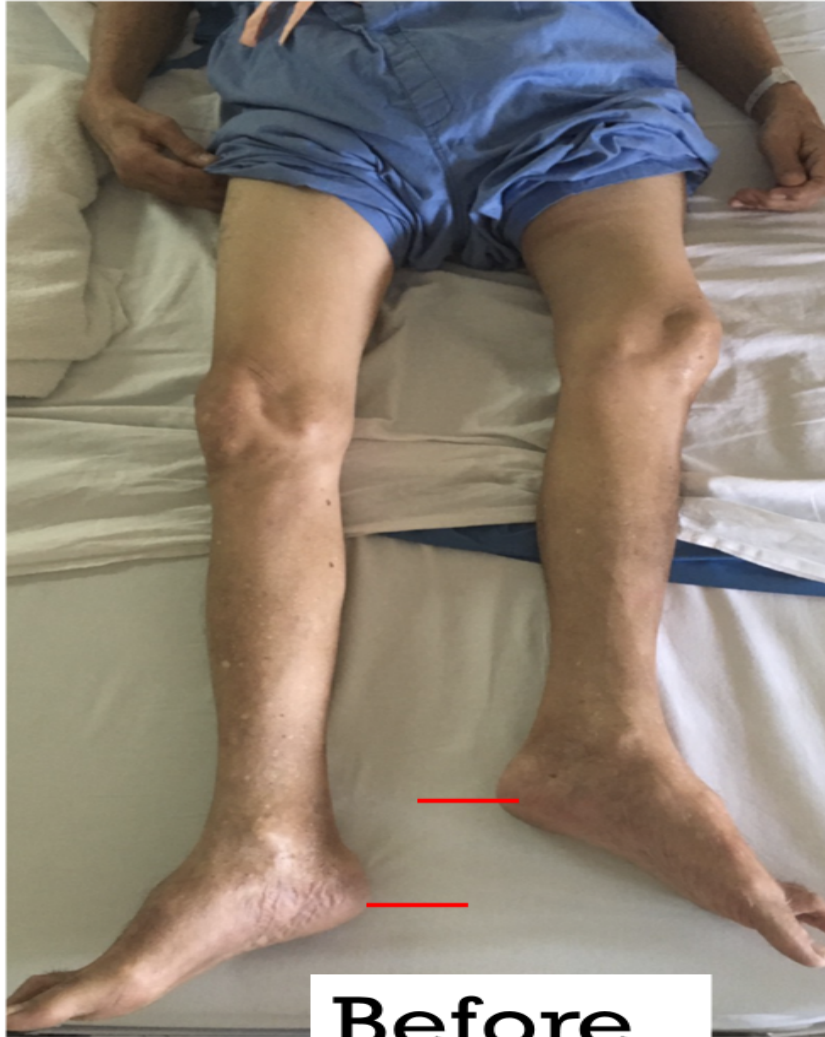



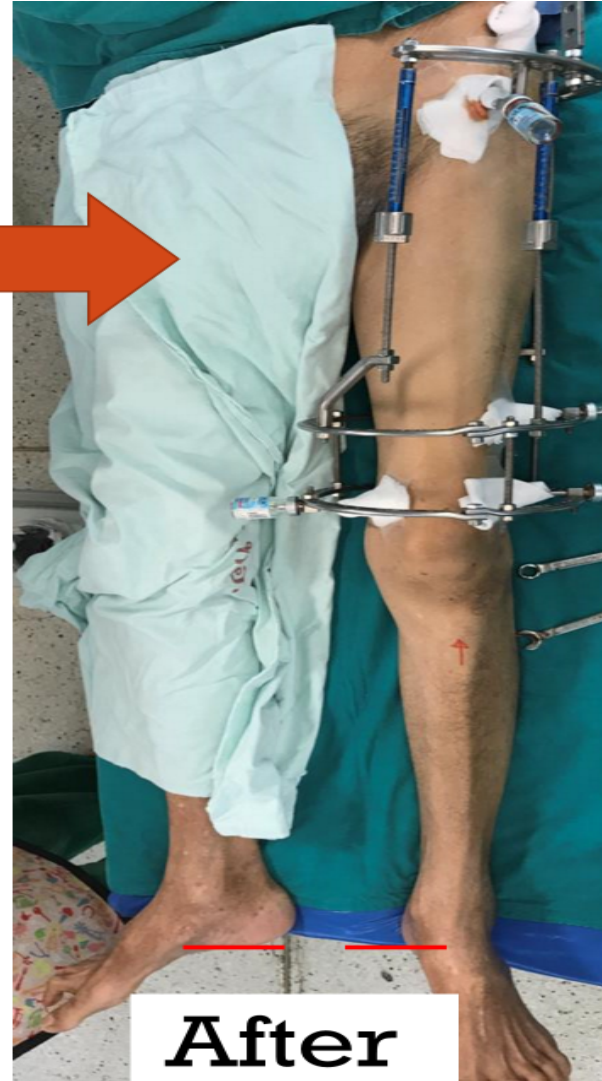3 weeks

Gradual Distraction





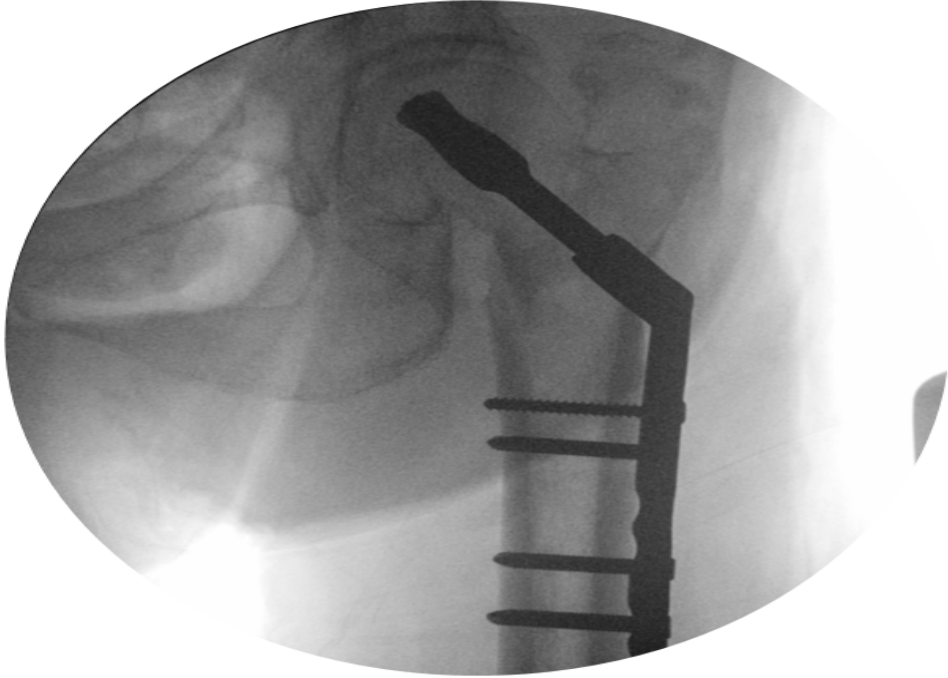
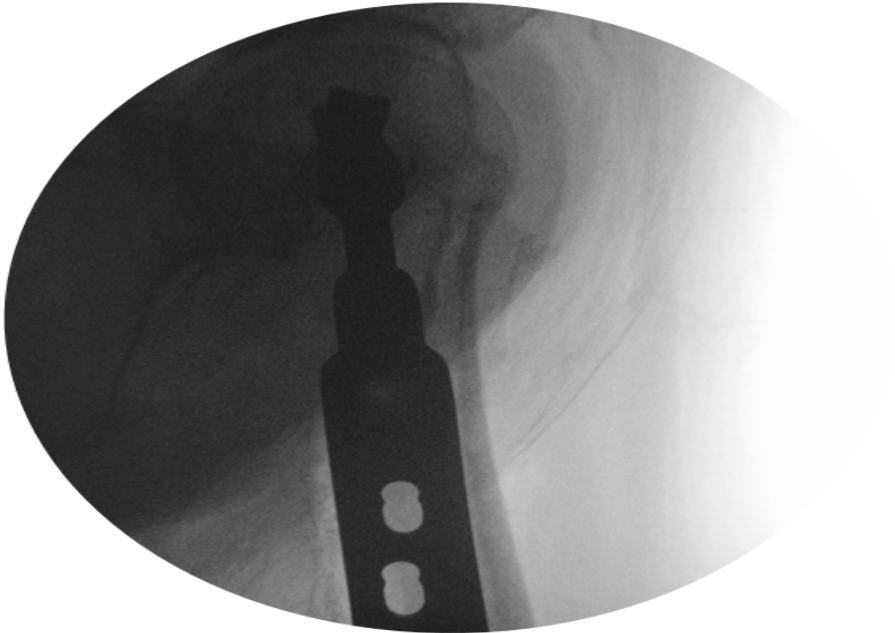
Before



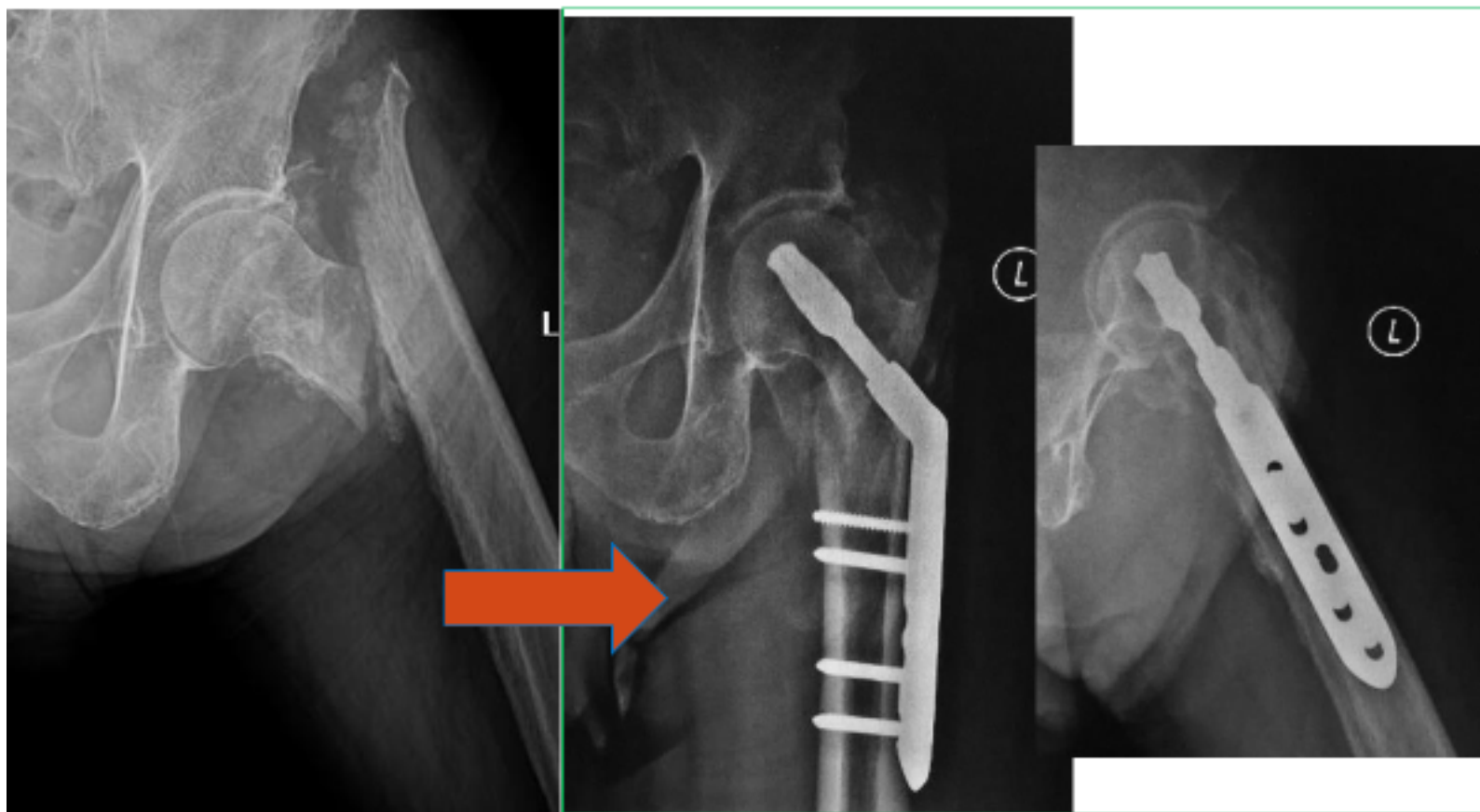
After



Intraop definitive fixation DH Blade

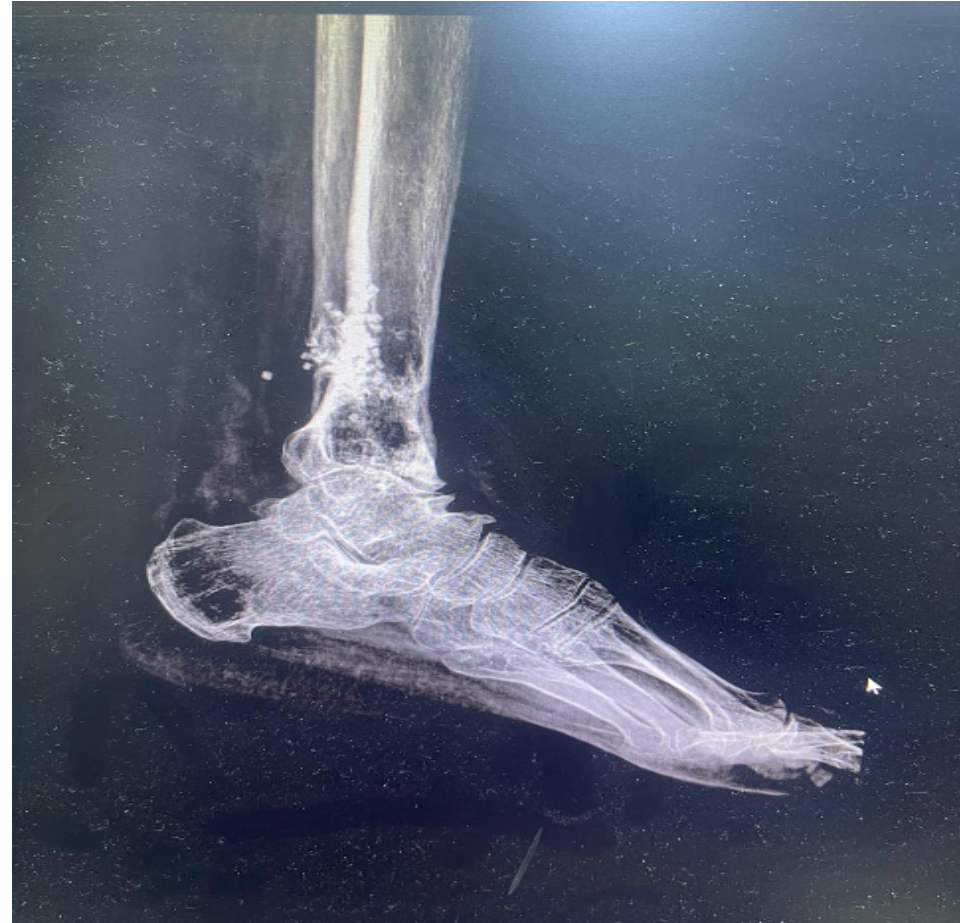
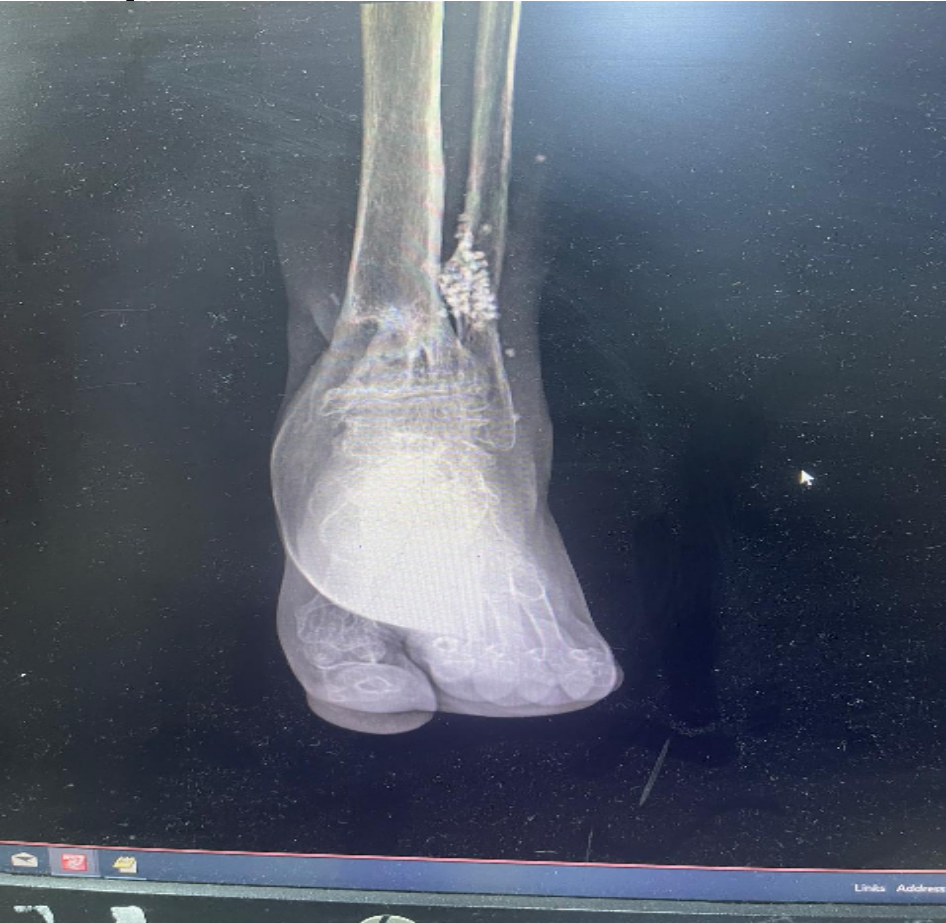
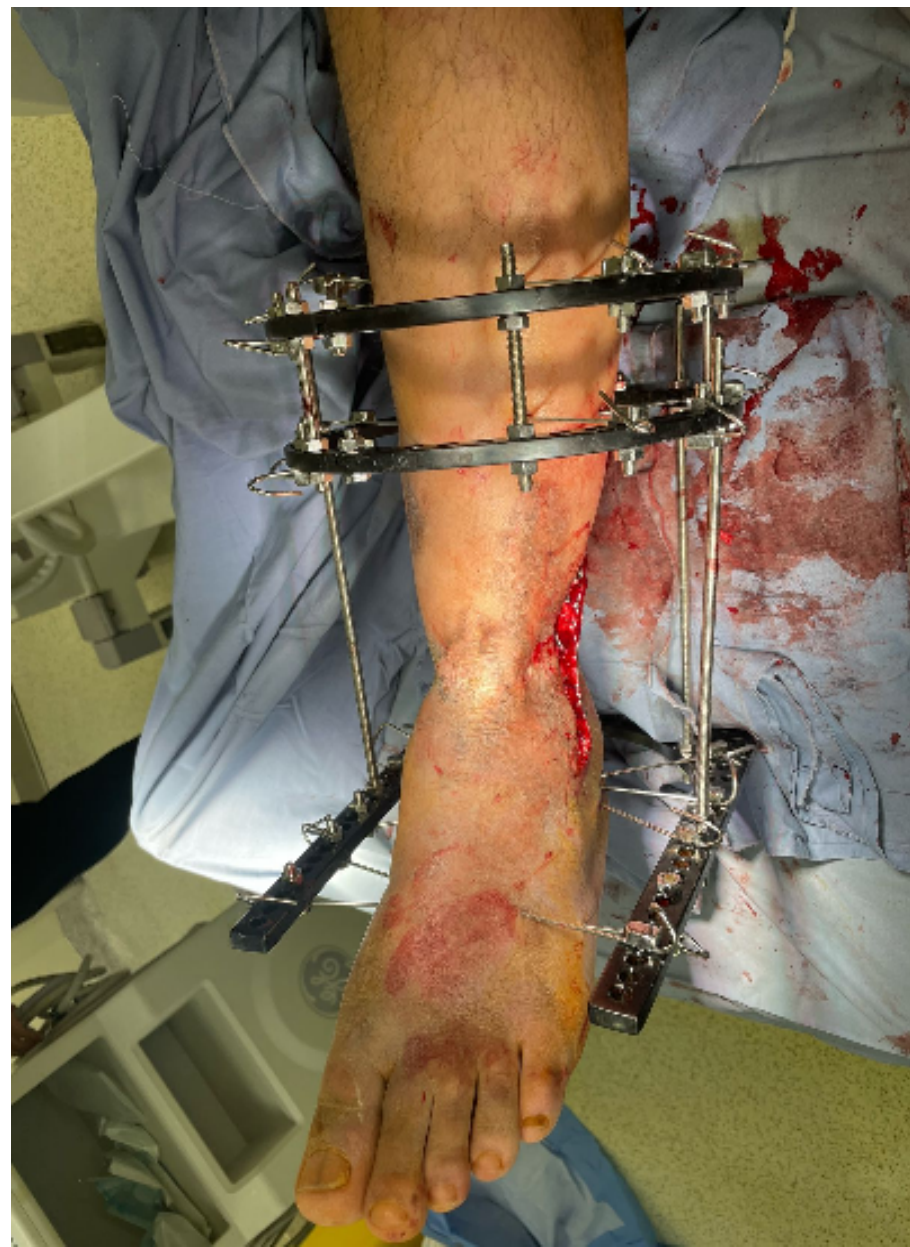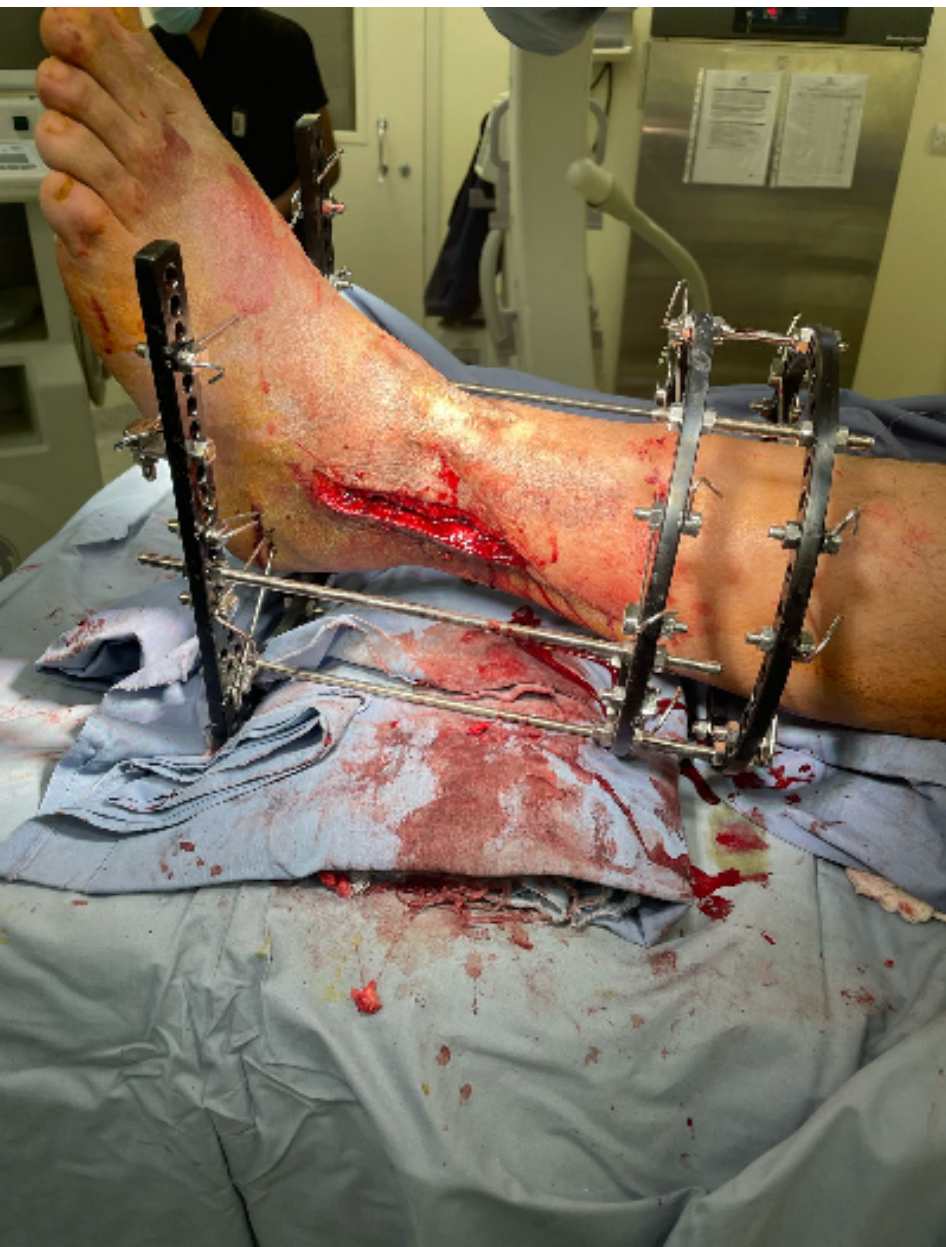5 months

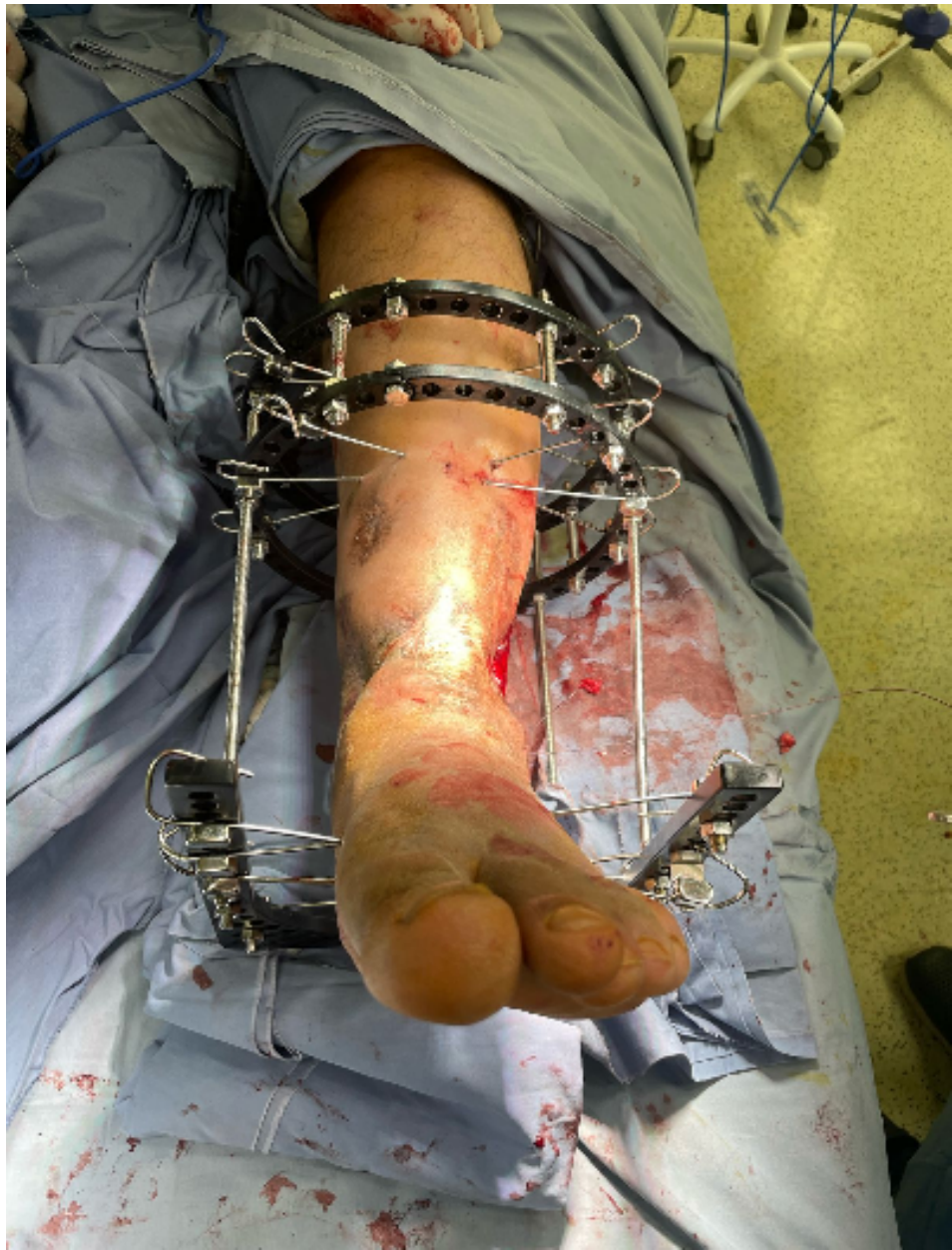

Case 3

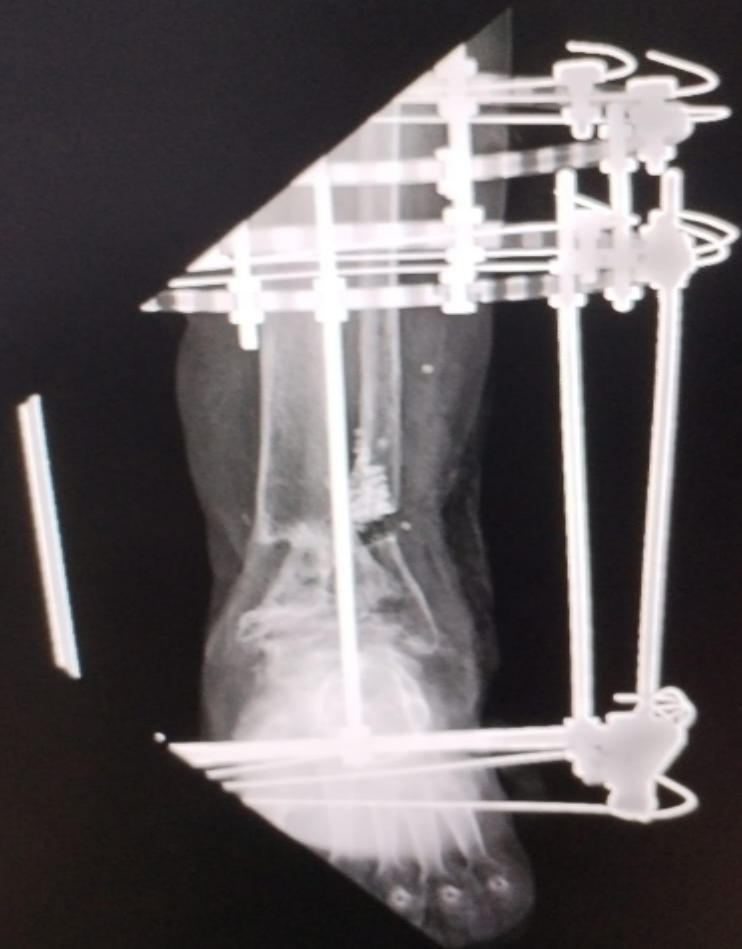38 male severe ankle O.A post trauma complicated by infection





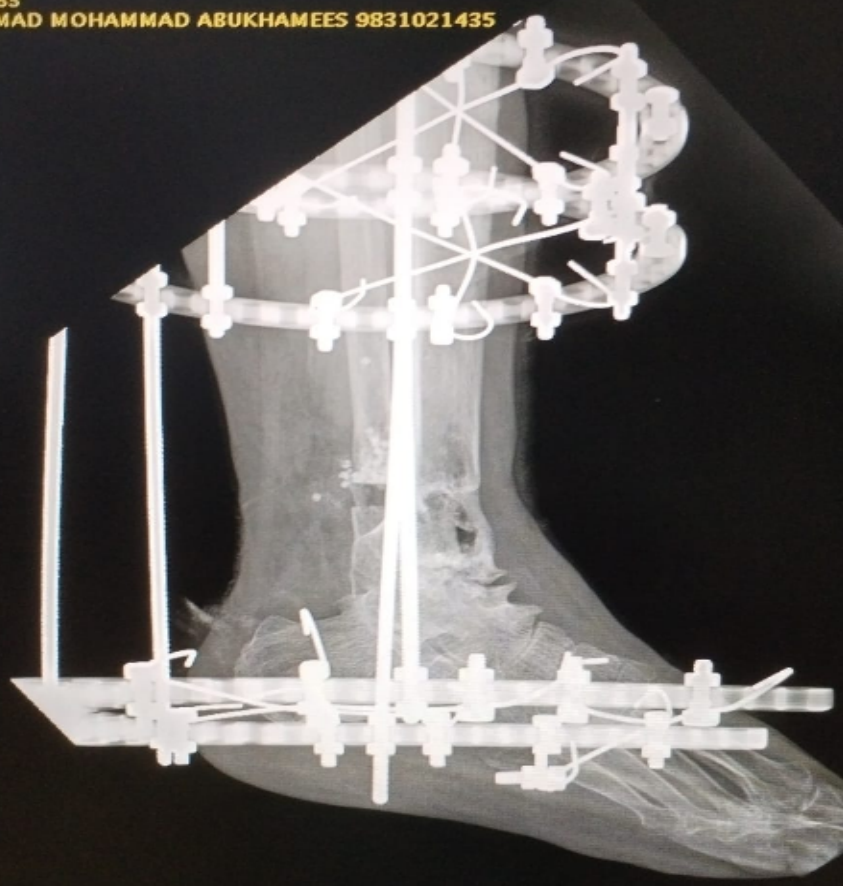


Jan-2025 16:07:32
: 07-Jan-1983
AMMAD,AHMAD MOHAMMAD ABUKHAMEES 9831021435
325-33270



Knee_antero-posterior_Standard_MEDIUM ADULT_Factory4 Edge 7
Processed: 23-Jan-2025 16:07:34
R antero-posterior Knee

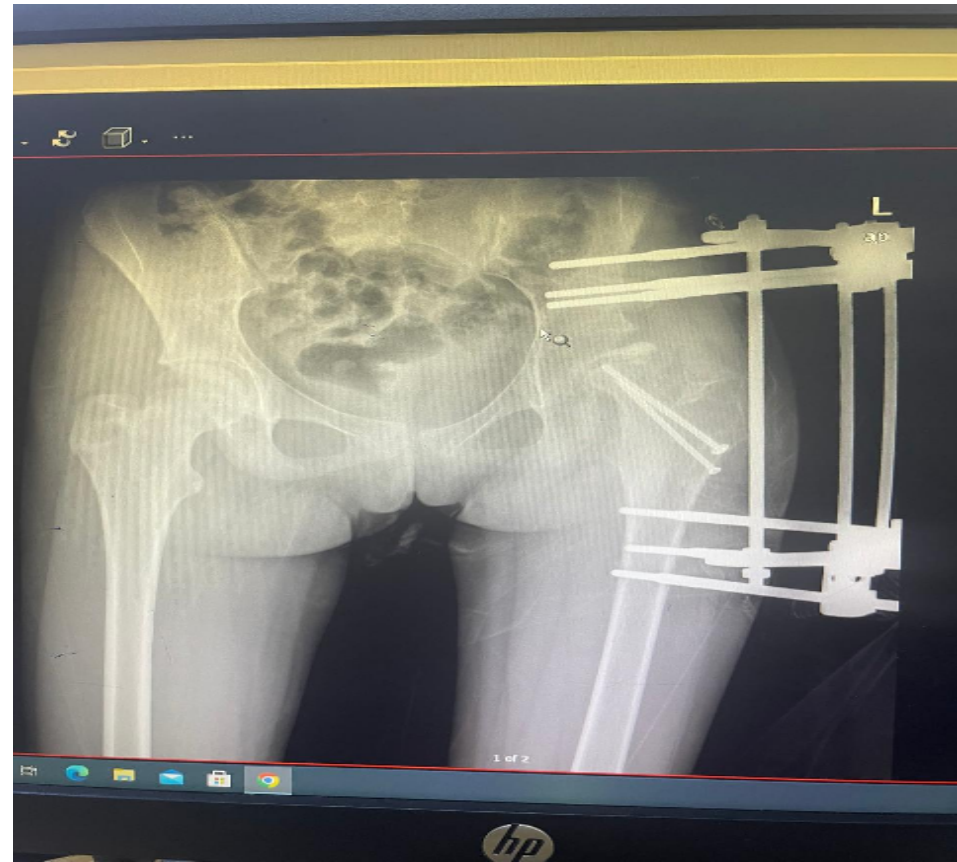
16:08:28
983
AMMAD MOHAMMAD ABUKHAMEES 9831021435



posterior_Standard_MEDIUM ADULT_Factory4 Edge 7
-Jan-2025 16:08:30
terior Knee

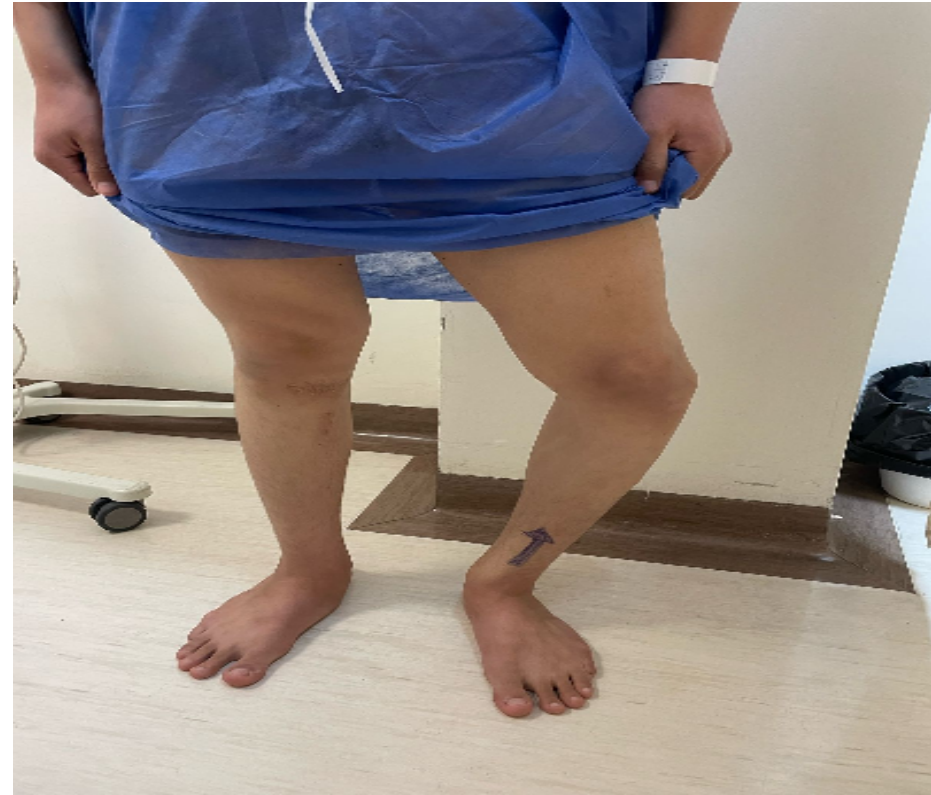Case 4

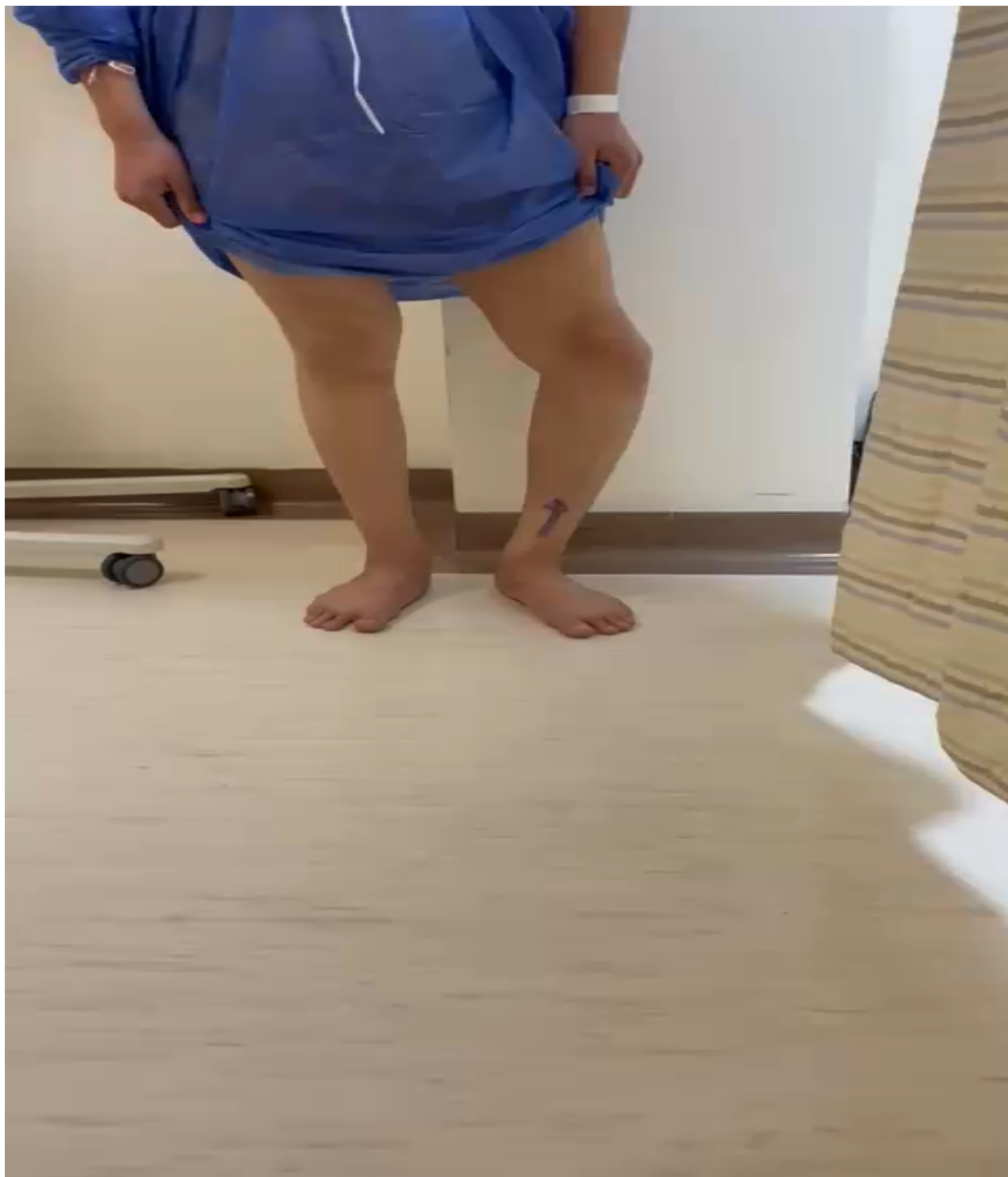15 female HIP AVN post Nof cannulated screw's

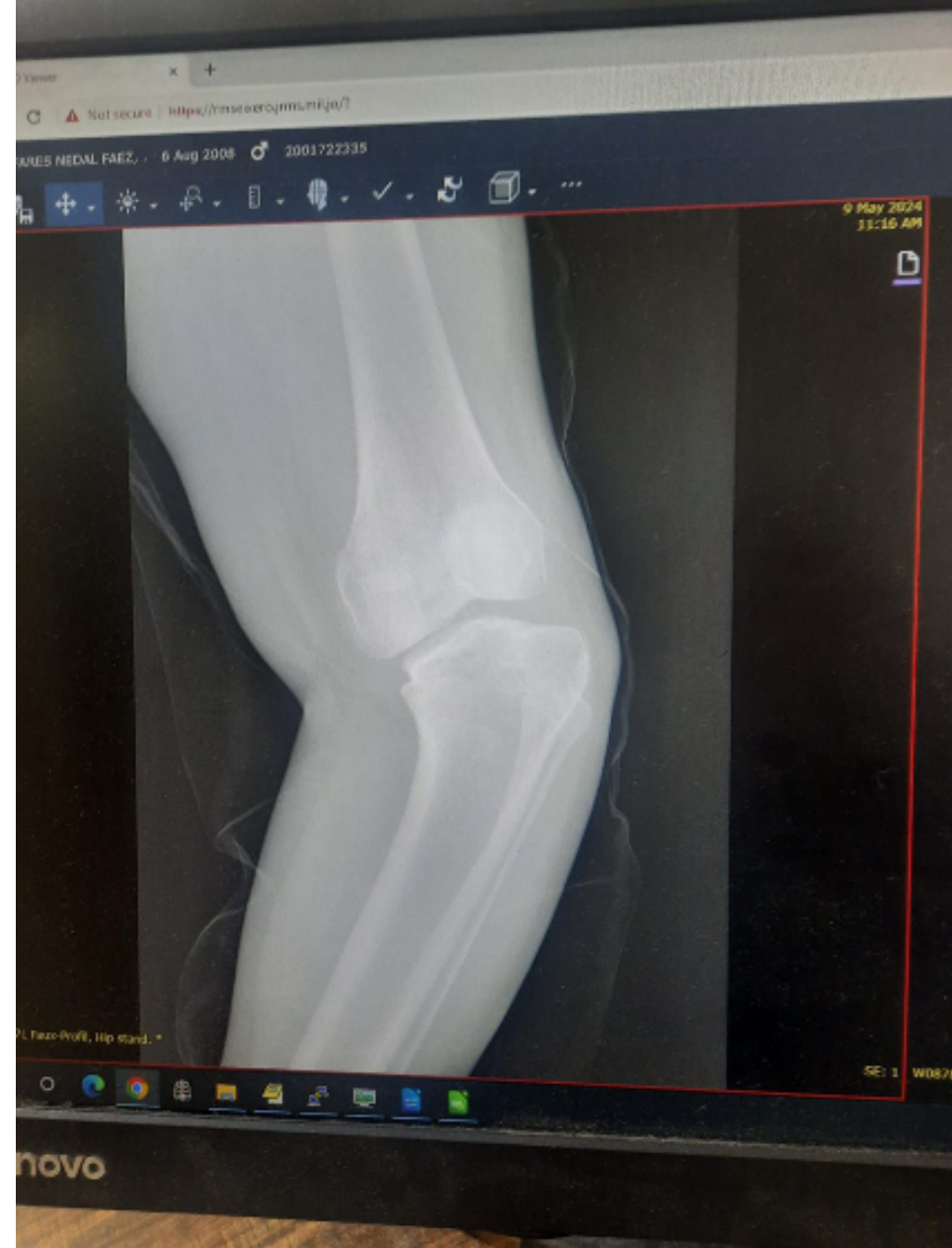
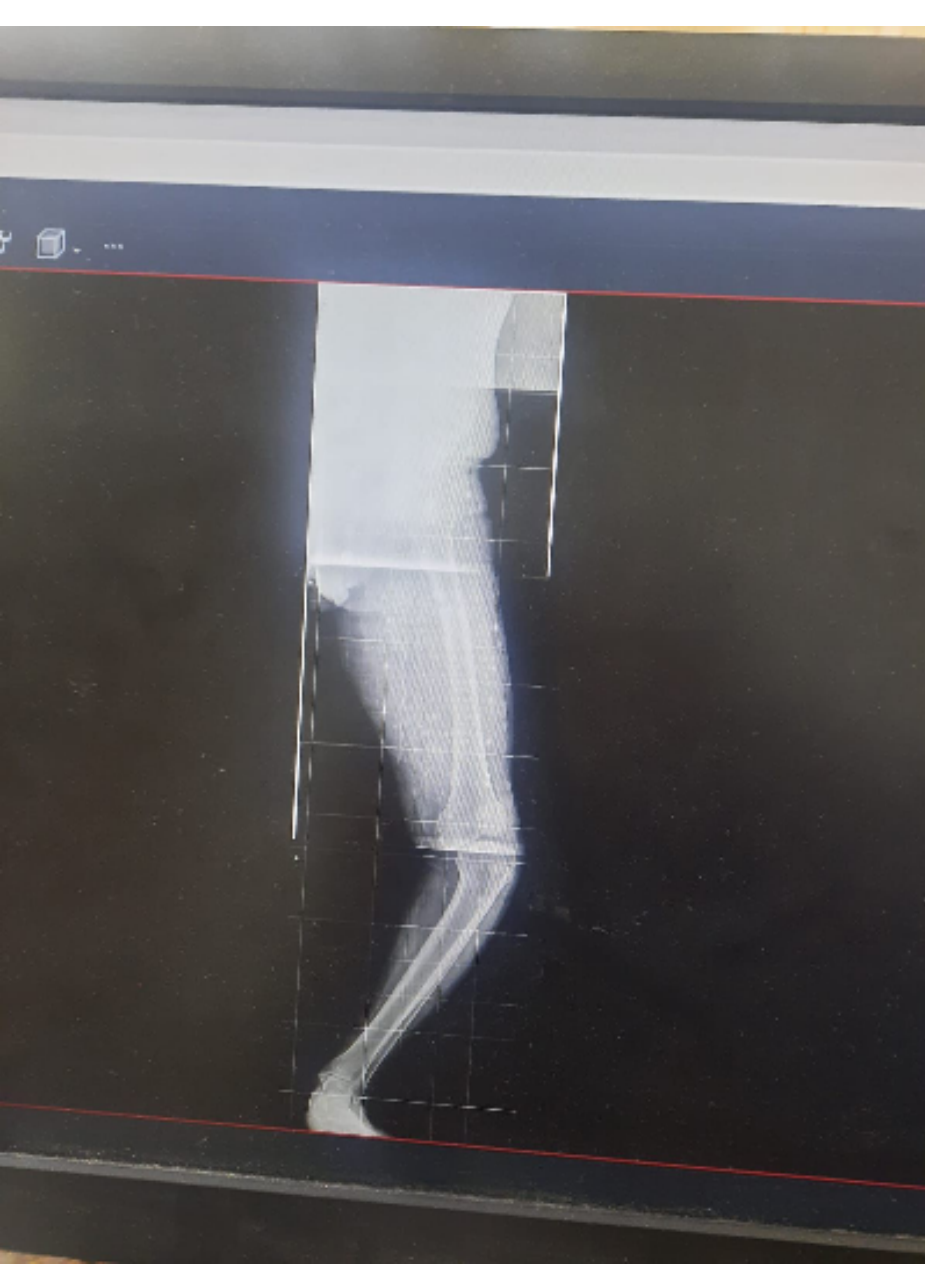
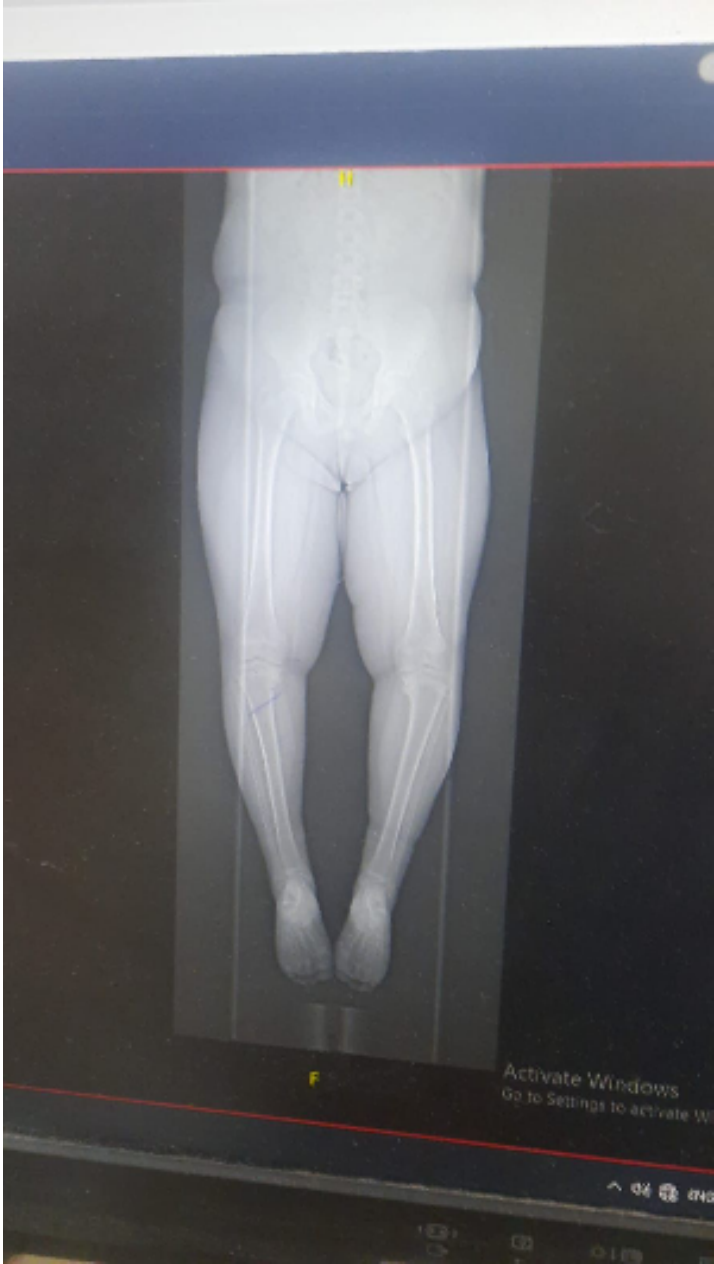Case 5

17 y LT SEVERE GENU VARUM (BLOUNT DISEASE)

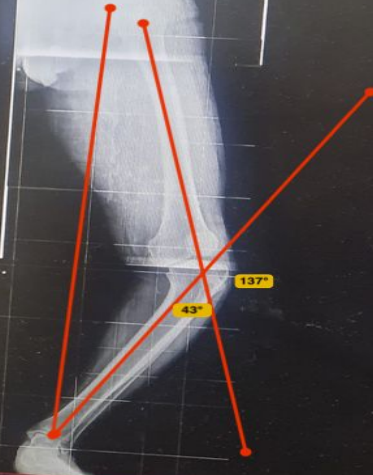
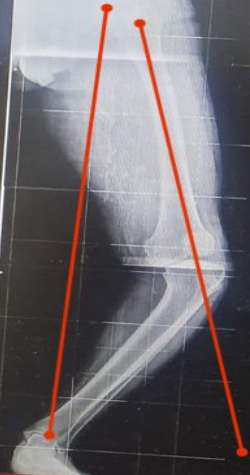


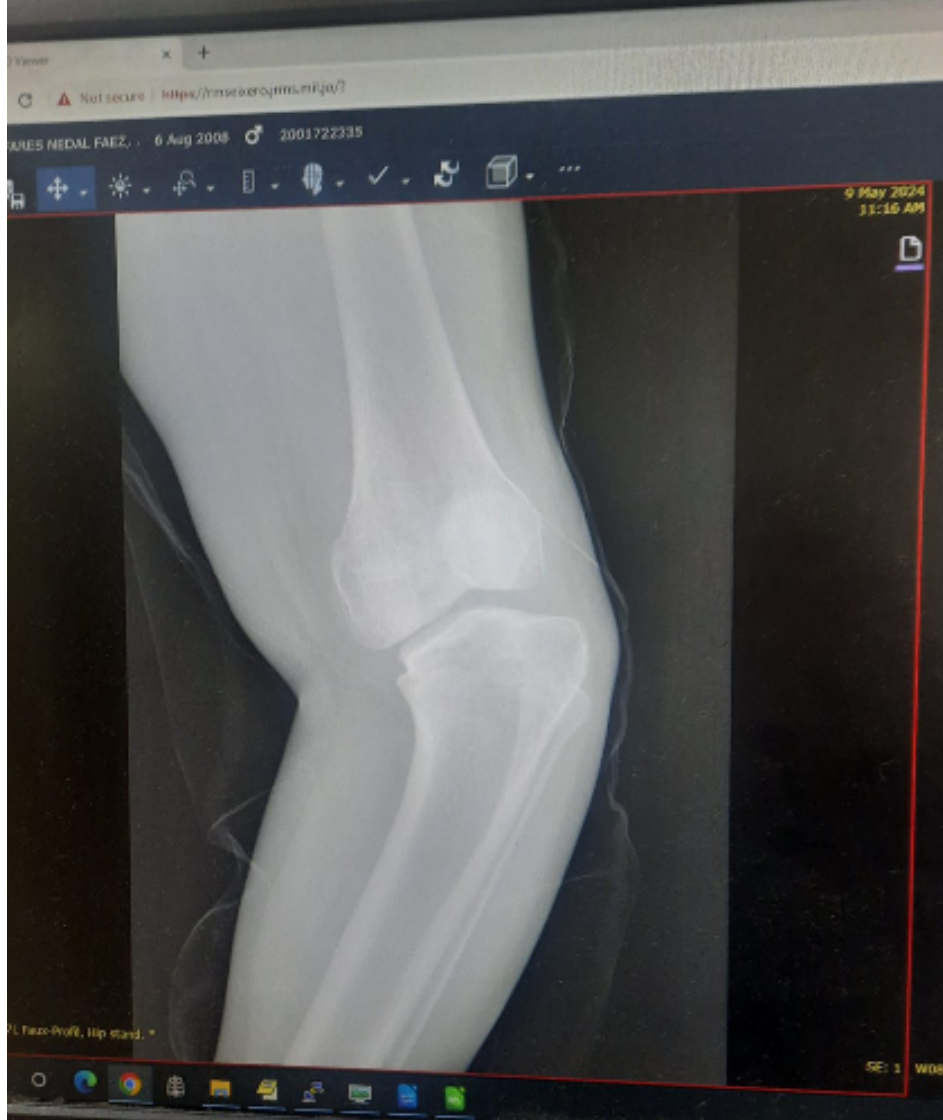
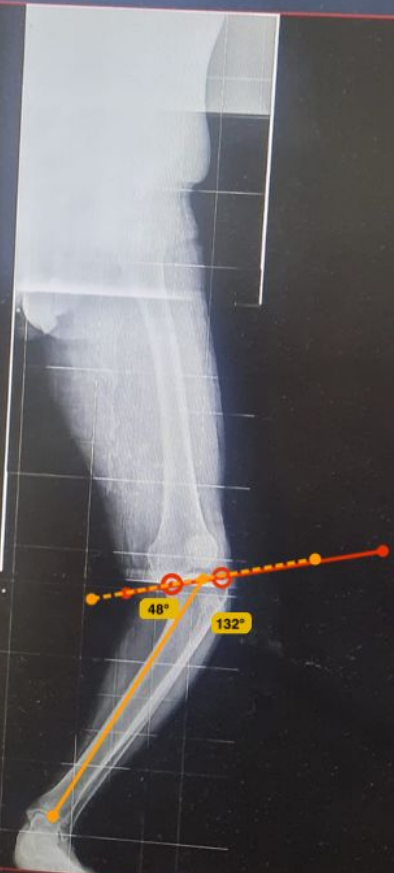
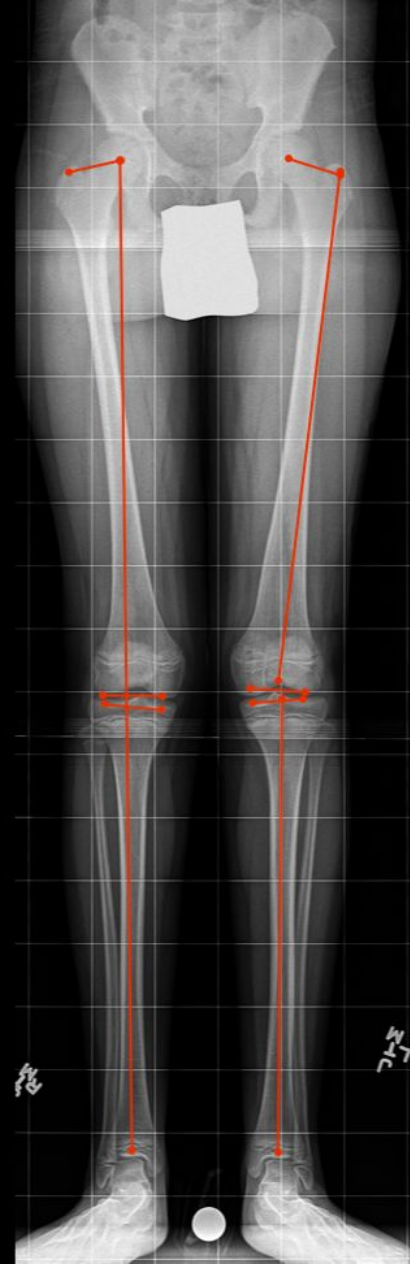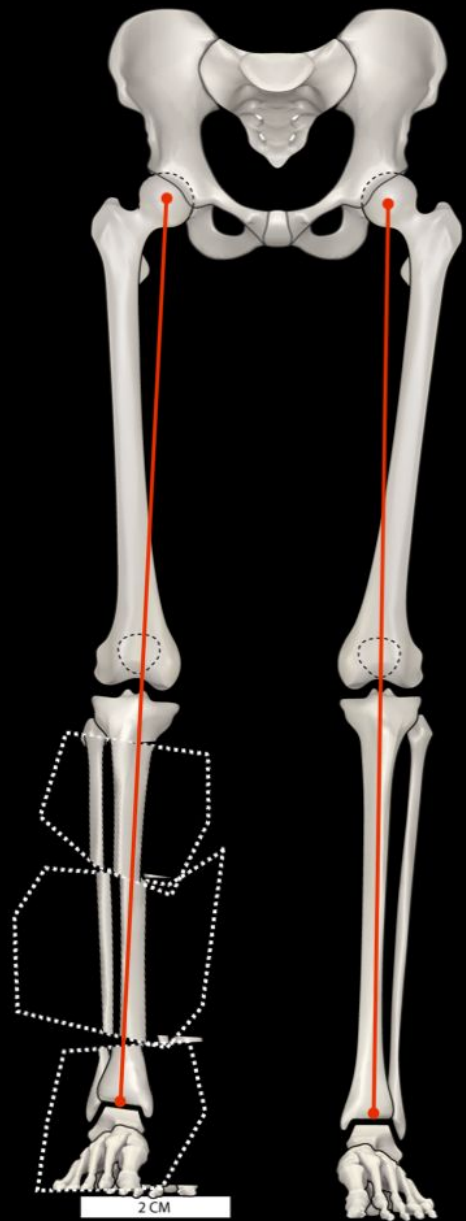


Deformity Analysis

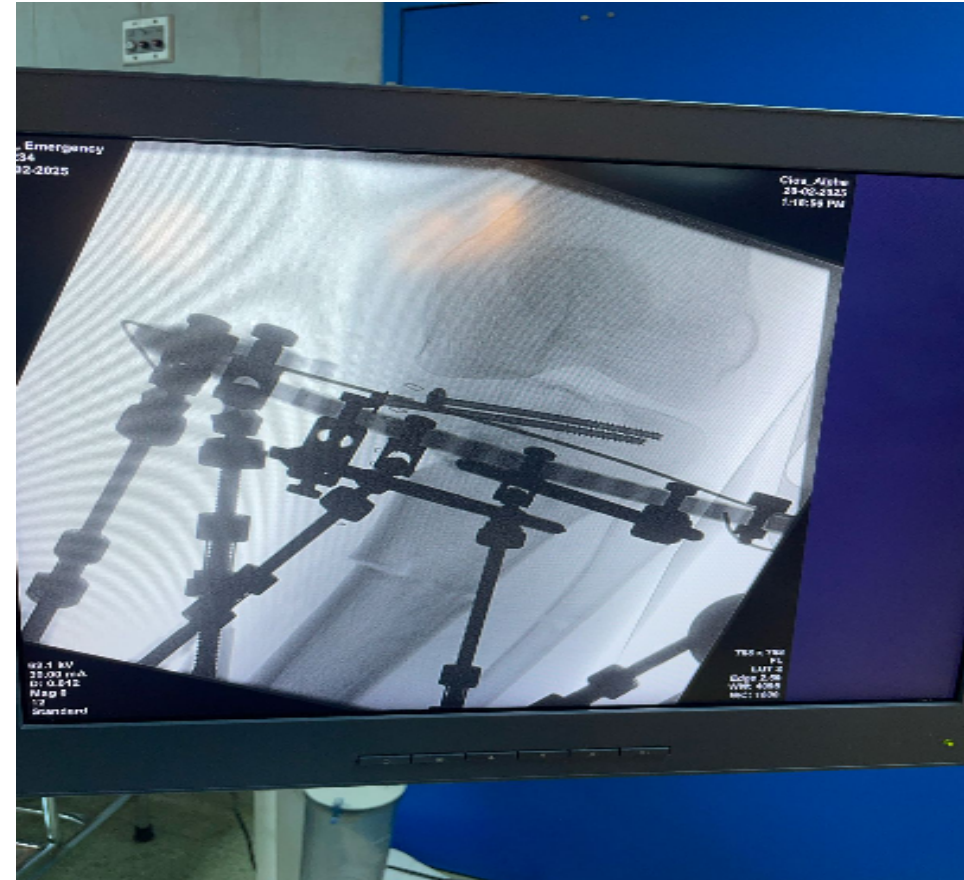
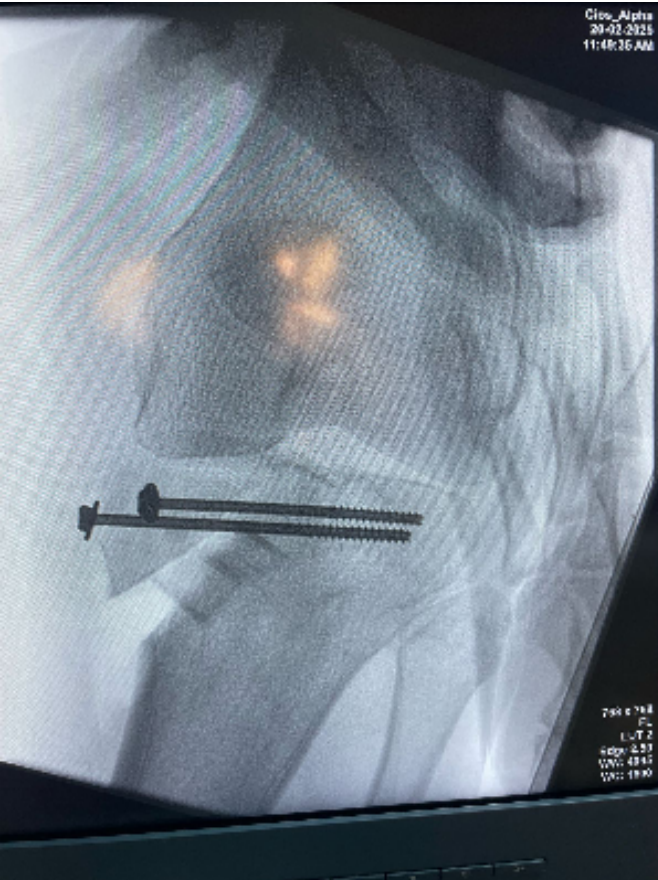


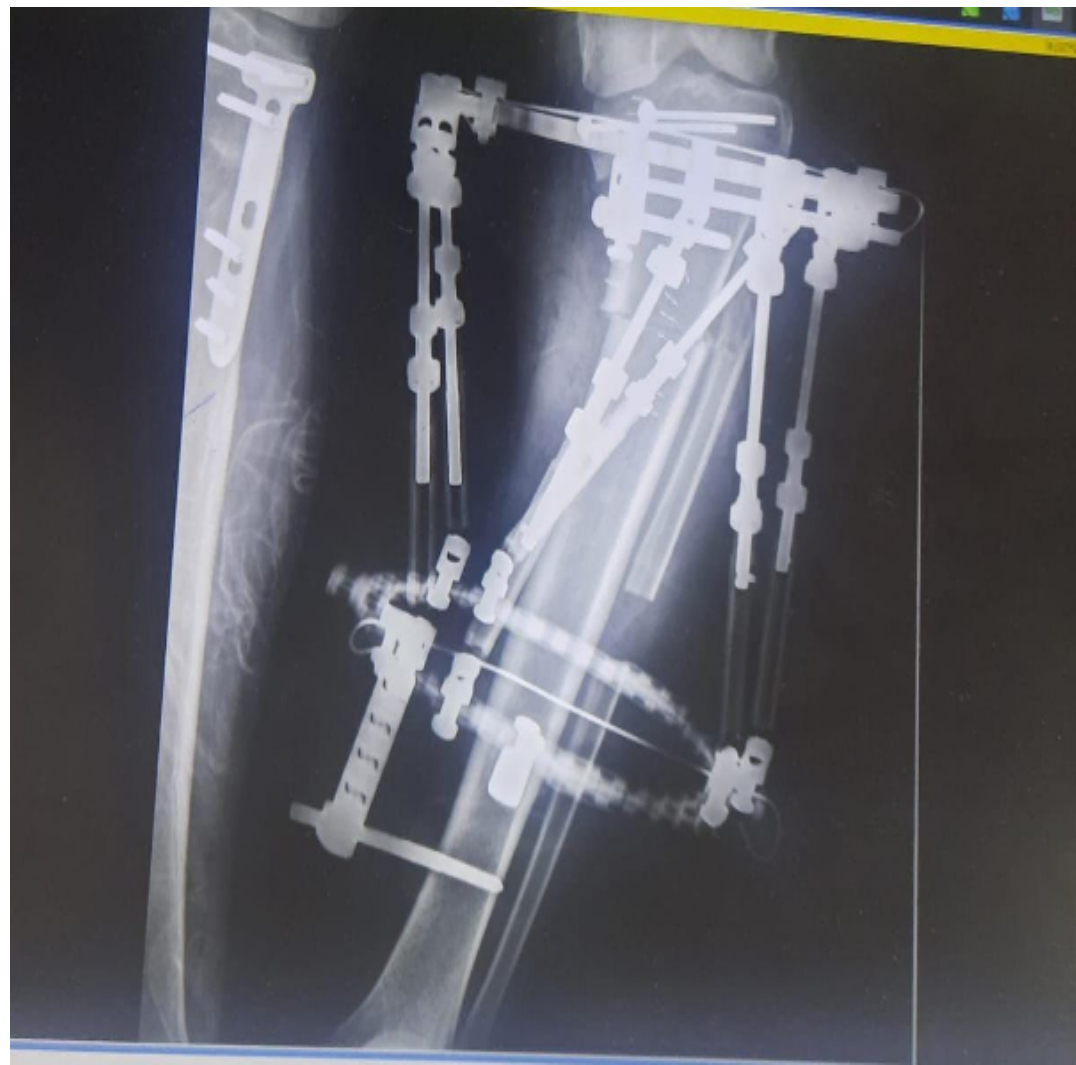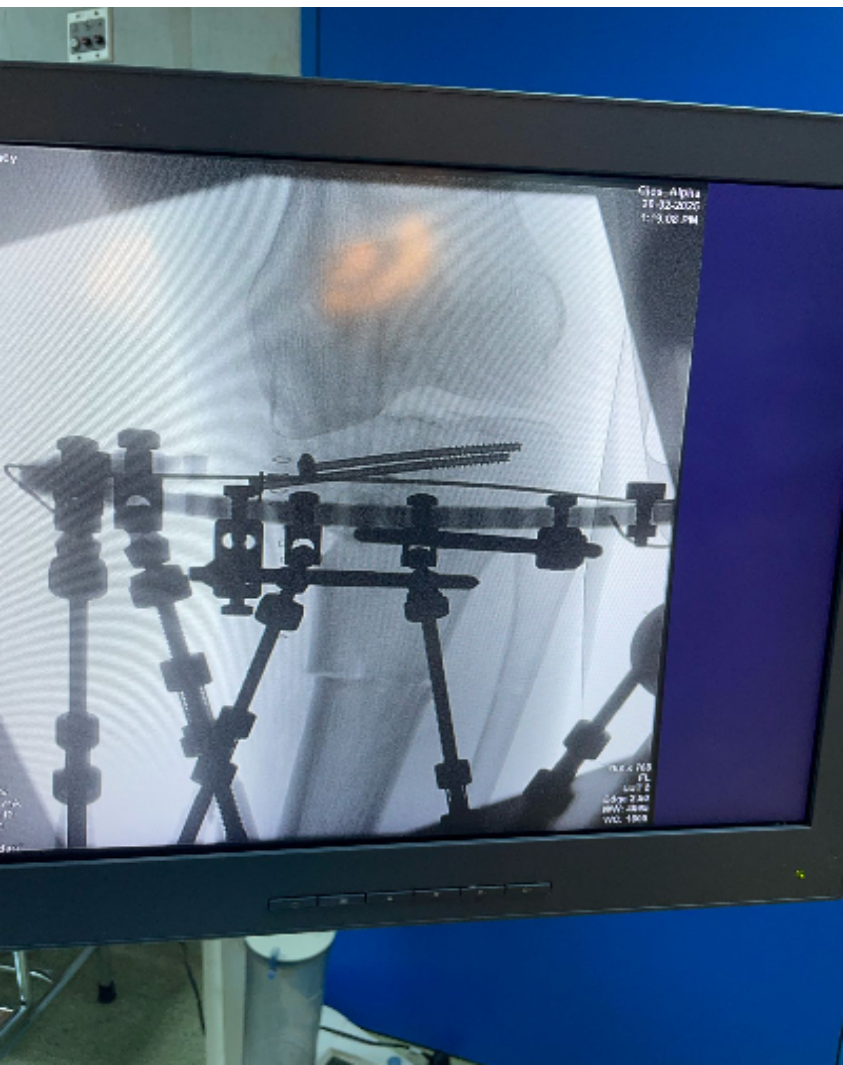


lenovo



JOINT LEVELING PROCEDURE AND FRAME APPLIED FOR GRADUAL CORRECTION





THANK YOU